



OPEN ACCESS

# European evidence-based guidelines on pancreatic cystic neoplasms

The European Study Group on Cystic Tumours of the Pancreas

## Correspondence to

The European Study Group on Cystic Tumours of the Pancreas, Pancreatic Surgery Unit, Division of Surgery, Department of Clinical Science, Intervention and Technology (CLINTEC), Center for Digestive Diseases, Karolinska Institutet, Karolinska University Hospital, Stockholm 14186, Sweden; marco.del.chiaro@ki.se

Received 15 January 2018  
Revised 13 February 2018  
Accepted 13 February 2018

## ABSTRACT

Evidence-based guidelines on the management of pancreatic cystic neoplasms (PCN) are lacking. This guideline is a joint initiative of the European Study Group on Cystic Tumours of the Pancreas, United European Gastroenterology, European Pancreatic Club, European-African Hepato-Pancreato-Biliary Association, European Digestive Surgery, and the European Society of Gastrointestinal Endoscopy. It replaces the 2013 European consensus statement guidelines on PCN. European and non-European experts performed systematic reviews and used GRADE methodology to answer relevant clinical questions on nine topics (biomarkers, radiology, endoscopy, intraductal papillary mucinous neoplasm (IPMN), mucinous cystic neoplasm (MCN), serous cystic neoplasm, rare cysts, (neo)adjuvant treatment, and pathology). Recommendations include conservative management, relative and absolute indications for surgery. A conservative approach is recommended for asymptomatic MCN and IPMN measuring <40 mm without an enhancing nodule. Relative indications for surgery in IPMN include a main pancreatic duct (MPD) diameter between 5 and 9.9 mm or a cyst diameter ≥40 mm. Absolute indications for surgery in IPMN, due to the high-risk of malignant transformation, include jaundice, an enhancing mural nodule >5 mm, and MPD diameter >10 mm. Lifelong follow-up of IPMN is recommended in patients who are fit for surgery. The European evidence-based guidelines on PCN aim to improve the diagnosis and management of PCN.

## INTRODUCTION

Pancreatic cystic neoplasms (PCN) are estimated to be present in 2–45% of the general population.<sup>1–4</sup> PCN comprise a clinically challenging entity as their biological behaviour ranges from benign to malignant disease. Consequently, correct management of PCN may prevent progression to pancreatic cancer while minimising the need for lifelong screening and related costs.<sup>5</sup> Unfortunately, it is often difficult to differentiate between the various types of PCN.<sup>6</sup> In 2013, the European Study Group on Cystic Tumours of the Pancreas, in association with United European Gastroenterology (UEG) and the European Pancreatic Club (EPC), published a European expert consensus statement on PCN.<sup>7</sup>

In 2016, as a group, these stakeholders felt that sufficient data were available to mandate an update of these guidelines. In contrast to the previous European,<sup>7</sup> and international<sup>8</sup> guidelines, an evidence-based approach was chosen. Similar to the previous European,<sup>7</sup> but in contrast to other (inter-)national

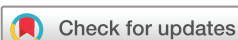guidelines,<sup>8,9</sup> the present guideline deals with all common PCN. The European evidence-based guidelines on PCN aim to improve the diagnosis and management of all PCN, and identify areas that require further research.

## METHODS

This guideline is a joint initiative of the European Study Group on Cystic Tumours of the Pancreas, the UEG, the EPC, the European-African Hepato-Pancreato-Biliary Association (E-AHPBA), European Digestive Surgery (EDS) and the European Society of Gastrointestinal Endoscopy (ESGE) and involves both European and non-European experts (online supplementary appendix 1).

A methodology committee (gastroenterologists, surgeons, radiologists, oncologists, endoscopists, basic scientists) identified the nine most important topics: biomarkers, radiology, endoscopy, intraductal papillary mucinous neoplasm (IPMN), mucinous cystic neoplasm (MCN), serous cystic neoplasm (SCN), rare cysts and (neo)adjuvant treatment and pathology. Next, multidisciplinary expert groups were formed and each assigned to one topic. In March 2016, each expert group received a list of questions about their topic. The groups could suggest changes and add relevant questions based on their expertise and available literature. Once all questions were finalised, the following steps were taken: (a) a systematic literature search was performed in the PubMed, Embase and Cochrane databases, and the systematic review included randomised or observational cohort studies with a minimum of 20 patients or systematic reviews on PCN, which were published in English, and available in full text; (b) based on the literature review, recommendations were formulated including a GRADE rating for the quality of the evidence and the strength of the recommendation<sup>10–12</sup>; (c) relevant remarks concerning the recommendations—for instance, about subgroups or availability of diagnostic/therapeutic strategies, were included; (d) a table of relevant studies was provided. The results of these evidence-based recommendations were presented and discussed at a plenary meeting of the European Study Group on Cystic Tumours of the Pancreas in October 2016 during the UEG week.

In January 2017, each expert group submitted the modified version of their task to the methodology committee. A synthesis of the work from different groups was completed in April 2017 (MDC and MGB) and this document was circulated and approved by all the group leaders. Finally, in October 2017, the final recommendations were discussed at a plenary meeting of the European



**To cite:** The European Study Group on Cystic Tumours of the Pancreas. *Gut* 2018;**67**:789–804.

**Table 1** Classification of cystic lesions of the pancreas

Epithelial neoplastic	Epithelial non-neoplastic
Intraductal papillary mucinous neoplasm all types	Lymphoepithelial cyst
Mucinous cystic neoplasm	Mucinous non-neoplastic cyst
Serous cystic neoplasm	Enterogeneous cyst
	Retention cyst/dysontogenetic cyst
	Peri-ampullary duodenal wall cyst
Serous cystadenocarcinoma	Endometrial cyst
Cystic neuroendocrine tumour G1–2	Congenital cyst (in malformation syndromes)
Acinar cell cystadenoma	
Cystic acinar cell carcinoma	
Solid pseudopapillary neoplasm	
Accessory-splenic epidermoid cyst	
Cystic hamartoma	
Cystic teratoma (dermoid cyst)	
Cystic ductal adenocarcinoma	
Cystic pancreatoblastoma	
Cystic metastatic epithelial neoplasm	
Others	
Non-epithelial neoplastic	Non-epithelial non-neoplastic
Benign non-epithelial neoplasm (eg, lymphangioma)	Pancreatitis-associated pseudocyst
Malignant non-epithelial neoplasms (eg, sarcomas)	Parasitic cyst

Study Group on Cystic Tumours of the Pancreas during the UEG week. Thereafter, in November 2017, all members of the expert groups were surveyed and asked about their agreement with the final recommendations on a five-point scale (ie, definitely agree, moderately agree, neutral, moderately disagree, definitely disagree) via an anonymous web-based vote. Recommendations with at least 75% consensus (combining 'definitely' and 'moderately' agree) were accepted as 'strong agreement'; otherwise 'weak agreement' was listed. The results of this survey were added to the evidence-based recommendation in order to provide readers with more insight into the level of agreement among experts. In December 2017, the members of the methodology committee and the group leaders approved the final draft.

Each statement includes the grade of evidence, strength of the recommendation, voting result and, where appropriate, remarks.

## Definitions

PCN are defined and classified according to the WHO criteria<sup>13</sup> (table 1). Disease-free survival was defined as the length of time the patient lives after primary treatment without any signs or symptoms of recurrence.

## RECOMMENDATIONS

This guideline aims to provide evidence-based guidelines for the diagnosis and treatment of PCN.

### 1 Biomarkers

1.1 What is the role of blood and cystic biomarkers in the diagnosis and follow-up of PCN in current clinical practice?

#### Blood

*There are no available DNA, RNA or protein biomarkers in blood for clinical use to differentiate pancreatic cyst type or identify high-grade dysplasia or cancer. Serum cancer antigen (CA) 19.9 may be considered in IPMN where there is concern for malignant transformation<sup>14–16</sup> (GRADE 2C, strong agreement).*

#### Cyst fluid

*DNA markers, in particular, mutations in GNAS and KRAS, have shown promise in identifying mucin-producing cysts. In cases in*

*which the diagnosis is unclear, and a change in diagnosis will alter management, analysis of these mutations using highly sensitive techniques, such as next-generation sequencing (NGS), may be considered<sup>17–20</sup> (GRADE 2C, strong agreement).*

*Currently, there is insufficient evidence to support the use of RNA or non-carcinoembryonic antigen (CEA) protein markers in pancreatic cysts (GRADE 1B, strong agreement).*

The role of CEA in cyst fluid is discussed in recommendation 3.4.

Additional biomarkers in the differential diagnosis of PCN are amylase/lipase levels. Amylase may exclude pancreatic pseudocysts (amylase <250 U/L; sensitivity 0.44, specificity 0.98), but does not differentiate between other non-mucinous and mucinous cysts.<sup>21–22</sup>

## 2 Radiology

2.1 What is the accuracy of MRI/cholangiopancreatography (MRI/MRCP) and CT for identifying the specific type of PCN?

*The reported accuracy for identifying the specific type of PCN is between 40% and 95% for MRI/MRCP and between 40% and 81% for CT.<sup>23–27</sup>*

PCN are increasingly being detected, with a reported prevalence of 2.1–2.6% for CT<sup>28–29</sup> and of 13.5–45% for MRI/MRCP,<sup>2–30–31</sup> with the difference between CT and MRI most probably due to the higher contrast resolution of MRI compared with CT and thus increased sensitivity but not specificity. However, the accuracy remains relatively low, using either single, or combining imaging modalities, for identifying the specific type of PCN,<sup>6</sup> for differentiating small PCN from non-neoplastic or non-epithelial cysts, or for connection to the ductal system.<sup>6–32</sup>

2.2 Which radiological (cross-sectional) imaging method is preferred for the surveillance of patients with PCN taking into consideration accuracy, cost, and modality-related risk factors?

*Pancreatic MRI is the preferred method for follow-up of PCN (GRADE 2C, strong agreement).*

Dedicated pancreatic protocol CT and pancreatic MRI/MRCP are reported to have a similar accuracy for the characterisation of PCN.<sup>33–35</sup> MRI/MRCP is more sensitive than CT for identifying communication between a PCN and the pancreatic duct system, and the presence of a mural nodule or internal septations. In addition, MRI/MRCP is very sensitive for identifying whether a patient has single or multiple PCN, with the latter favouring a diagnosis of multifocal side-branch IPMN.<sup>25–33–36–37</sup> Patients with PCN may require lifelong imaging follow-up. This is important, as studies have shown that repeated exposure to ionising radiation following CT increases the risk of malignancy.<sup>38–39</sup>

2.3 Are there specific clinical scenarios where use of one cross-sectional imaging modality (CT/MRI) instead of another, or combined use is preferable?

*In general, MRI is the preferred method for the investigation of patients with PCN. Multimodality imaging should be considered in cases where the identification of calcification is important, for tumour staging, or for diagnosing postoperative recurrent disease (GRADE 2C, strong agreement).*

The use of CT should be considered in the following clinical situations:

- For the detection of parenchymal, mural or central calcification, and especially when differentiating pseudocysts associated with chronic pancreatitis from PCN.<sup>40–41</sup>

- b. When there is suspicion of a malignant PCN or concomitant pancreatic cancer, and when assessment of vascular involvement, peritoneal, or metastatic disease is required.
- c. When there is suspicion of postoperative recurrence of pancreatic cancer.

#### 2.4 What are the minimum technical requirements for MRI or CT for the diagnosis and surveillance of patients with PCN?

*No definite MRI or CT protocol can be recommended for the diagnosis or surveillance of patients with PCN because of the wide spread of published data and the lack of dedicated comparative studies (GRADE 2C, strong agreement).*

In 2016, a short protocol for the surveillance of PCN that included T2-weighted ultrafast spin echo technique (T2-HASTE) and T1-weighted pre-contrast imaging was found in one retrospective study to provide equivalent information to a longer protocol which included diffusion-weighted imaging (DWI) and contrast enhanced T1-weighted sequences.<sup>42</sup> DWI may be added to this short protocol in order to minimise the risk of missing a concomitant pancreatic cancer. A combination of T2-HASTE and DWI has been shown to have similar accuracy to a comprehensive contrast-enhanced MRI protocol for the detection of pancreatic cancer.<sup>43</sup> A recent study suggested that MRI with MRCP has a better diagnostic performance than endoscopic ultrasound (EUS) for differentiating malignant from benign pancreatic IPMN and MCN,<sup>44</sup> but conclusive evidence is lacking.

### 3 Endoscopy

#### 3.1 What are the indications for performing EUS in PCN?

*EUS is recommended as an adjunct to other imaging modalities (GRADE 2C, strong agreement).*

*EUS is helpful for identifying PCN with features that should be considered for surgical resection. Similar to MRI and CT (see 3.1 statement), EUS is imperfect at identifying the exact type of PCN (GRADE 2C, strong agreement).*

*EUS is recommended if the PCN has either clinical or radiological features of concern identified during the initial investigation or follow-up (GRADE 2C strong agreement).*

Data for EUS-based differentiation between benign and malignant PCN are conflicting.<sup>45–48</sup> In addition, there is considerable interobserver variation in EUS-based diagnoses.<sup>49 50</sup>

#### 3.2 When should contrast harmonic enhanced EUS (CH-EUS) be performed for PCN and does it alter management?

*CH-EUS should be considered for further evaluation of mural nodules. CH-EUS is also helpful in assessing vascularity within the cyst and septations (GRADE 2C, strong agreement).*

*The presence of hyperenhancement of a mural nodule, solid mass, or septations on CH-EUS raises concern for malignant transformation, and EUS-fine needle aspiration (FNA) of the lesion should be considered (GRADE 2C, strong agreement).*

CH-EUS seems superior to standard EUS and CT for the identification of mural nodules.<sup>51 52</sup> Interobserver agreement is excellent for Sonazoid, and moderate for Sonovue.<sup>51 53</sup>

#### 3.3 What are the indications and contraindications for EUS-FNA for PCN?

*EUS-FNA improves diagnostic accuracy in PCN for differentiating mucinous versus non-mucinous PCN, and malignant versus benign PCN, in cases where CT or MRI are unclear (GRADE 2C, strong agreement).*

*A combined analysis of cyst fluid CEA, cyst fluid lipase levels, and cytology provides the highest accuracy for differentiating mucinous from non-mucinous PCN (GRADE 2C, strong agreement).*

*EUS-FNA should only be performed when the results are expected to change clinical management (GRADE 2C, strong agreement).*

*EUS-FNA should not be performed if the diagnosis is already established by cross-sectional imaging, or where there is a clear indication for surgery (GRADE 2C, strong agreement).*

*Relative contraindications for EUS-FNA in PCN is a distance of >10 mm between the cyst and the transducer, the presence of a high-risk of bleeding due to bleeding disorder, or the use of dual antiplatelet drugs (GRADE 2C, strong agreement).*

The role of EUS-FNA in the diagnosis of PCN is still a matter of debate and consensus in the literature is lacking.<sup>54 55</sup>

#### 3.4 When EUS-FNA is performed, which tests should be performed and what is their yield?

*Evaluation of cyst fluid CEA, combined with cytology, or KRAS/ GNAS mutation analyses (although the latter is not yet standard management), may be considered for differentiating an IPMN or MCN from other PCN (GRADE 2C, strong agreement).*

*To differentiate benign PCN from those harbouring high-grade dysplasia or cancer, EUS-FNA may be considered, and any solid component or thickened cyst wall targeted for cytology (GRADE 2C, strong agreement).*

*Brush cytology, and forceps biopsy are not recommended owing to a lack of high-quality evidence. Further studies are required before these tests can be considered in clinical practice (GRADE 1C, strong agreement).*

In a recent meta-analysis cytological analysis of cyst fluid had 42% sensitivity and 99% specificity for differentiating mucinous from non-mucinous PCN.<sup>56</sup> A cyst fluid CEA level of  $\geq 192$  ng/mL can distinguish mucinous, from non-mucinous cysts, with a sensitivity of 52–78% and specificity of 63–91%.<sup>57–64</sup> Differentiating between MCN and IPMN based on CEA and/or cytology is not possible and CEA seems inaccurate to differentiate between benign mucinous cysts and cysts with high-grade dysplasia or an associated invasive carcinoma.<sup>65</sup>

#### 3.5 What is the diagnostic performance of EUS +/-FNA?

*EUS morphology alone has a modest diagnostic yield (GRADE 2C, strong agreement).*

*EUS-FNA is recommended to achieve a better performance for diagnosing PCN (GRADE 1C, strong agreement).*

The reported accuracy of EUS morphology alone for differentiating mucinous from non-mucinous PCN is relatively low (48–94%),<sup>54 58 59 66 67</sup> with a sensitivity of 36–91%, and a specificity of 45–81%.<sup>54 58 59 66</sup> Although cytology is highly specific (83–100%),<sup>54 58 59 66 68</sup> it is relatively insensitive (27–48%),<sup>54 58 59 66 68</sup> resulting in low diagnostic accuracy (8–59%).<sup>58 59 66</sup>

Combination tests, such as EUS morphology, cytology and cyst fluid CEA, provide greater accuracy in detecting mucinous PCN than either EUS morphology or cytology alone.<sup>58 59</sup>

#### 3.6 What are the potential adverse events associated with EUS-FNA of PCN? Are there any measures that can be taken to prevent complications?

*EUS-FNA for PCN is a safe procedure with a relatively low risk (3.4%) of complications (GRADE 2B, strong agreement).*

*No specific measures are suggested to minimise the risk of complications in EUS-FNA (GRADE 2C, strong agreement).*



Following EUS-FNA, 44/1313 (3.4%) patients developed an adverse event.<sup>69–75</sup> These complications were mild in 34, moderate in nine, and severe in one patient(s). One retrospective study of 253 patients found that antibiotic prophylaxis had no effect on the risk of infection (7% vs 9.3%), although conclusive evidence is lacking.<sup>76</sup> Current practice is often a single shot antibiotic treatment after EUS-FNA of a cystic lesion.

### 3.7 Is there any role for endoscopic retrograde

cholangiopancreatography (ERCP) and/or pancreatoscopy and/or confocal laser endomicroscopy (nCLE) in the diagnosis of PCN?

*ERCP should not be used as a diagnostic modality for differentiating PCN (GRADE 1C, strong agreement).*

*Pancreatoscopy may be used in selected cases to provide information on the location and extent of main duct (MD)-IPMN and can be useful in differentiating chronic pancreatitis from MD-IPMN (GRADE 2C, weak agreement).*

*nCLE should not be used for the differential diagnosis of PCN (GRADE 1C, weak agreement).*

ERCP has a higher risk of adverse events, and a lower sensitivity and specificity for identifying the type of PCN than conventional radiology and EUS, and should not be used for this indication.<sup>77–78</sup>

The accuracy rate of pancreatoscopy is higher in MD-IPMN (88%) than in branch duct (BD)-IPMN (67%).<sup>79</sup> Intraoperative main pancreatic duct (MPD) pancreatoscopy combined with frozen section of intraductal biopsies may be helpful in establishing the extent of IPMN involvement of the MPD, and assist surgical decision-making about the extent of resection required.<sup>80</sup> Although promising, further studies are required and it should not be used in routine clinical care. A major concern about nCLE is the rate of adverse events (7–9%).<sup>81–82</sup> Some suggest that nCLE could be useful in correctly diagnosing serous cystadenomas, and thereby might prevent unnecessary surgery in these patients.<sup>83–84</sup>

## 4 IPMN

### 4.1 What is the risk of malignant progression of an IPMN lesion and what risk factors are predictive of cancer progression?

*Jaundice, the presence of an enhancing mural nodule ( $\geq 5$  mm) or a solid component, positive cytology, or a MPD measuring  $\geq 10$  mm are highly predictive of malignancy and should be evaluated in all patients fit for surgery (GRADE 1B, strong agreement).*

*MPD dilatation between 5 and 9.9 mm, cystic growth-rate  $\geq 5$  mm/year, Increased level of serum CA 19.9 ( $>37$  U/mL), symptoms, enhancing mural nodules ( $<5$  mm), and/or a cyst diameter  $\geq 40$  mm are also associated with an increased risk for high-grade dysplasia or cancer (GRADE 1B, strong agreement).*

Nine studies, including 1510 surgically resected IPMN, have concluded that the presence of jaundice, a contrast-enhancing mural nodule or solid component, or MPD dilatation of  $\geq 10$  mm, has a positive predictive value for malignancy

of 56–89%.<sup>85–92</sup> Several series including surgically resected IPMN have reported a high risk of harbouring at least high-grade dysplasia or cancer of 37–91% even for a MPD size of 5–9.9 mm.<sup>93–95</sup> Several studies have recently identified serum CA 19.9 as an independent predictor of malignancy in IPMN.<sup>14–16</sup> Analyses of surgical series of patients with BD-IPMNs who have undergone surgical resection, have found that a mural nodule measuring  $\geq 5$  mm on EUS has a sensitivity of 73–85% and specificity of 71–100% for the presence of high-grade dysplasia or cancer.<sup>96–99</sup> The presence of a cyst size  $\geq 30$  mm, without any other radiological or clinical risk factors, has a positive predictive value for malignancy of between 27% and 33%.<sup>85–92</sup> Patients with an IPMN measuring  $\geq 30$  mm have a 5% risk of developing malignancy, from which they will die within 3 years, whereas the 5 years disease-free survival after resection of IPMN is 96%.<sup>100</sup> Even for BD-IPMN  $<30$  mm, the 5-year risk for developing malignancy is reported to be 45% if a cyst increases in size by  $>2$  mm/year.<sup>101</sup> One study, with imaging surveillance for 36 months, detected a 20-fold higher risk of malignant progression in IPMN whose size increased  $>5$  mm/year or had a total growth of 10 mm.<sup>102</sup> In predominantly surgical series the presence of new-onset diabetes, pancreatitis, and abdominal pain have been associated with malignancy at varying rates, indicating that the level of evidence for these risk factors is low.<sup>14–85–91</sup> Table 2 shows the risk of high-grade dysplasia or malignancy according to the dilatation of the main pancreatic duct in IPMN.

Follow-up of BD-IPMN is required as progression of disease is expected in about 10–15% of patients during 3–5 years of follow-up. Surveillance should also include the entire pancreatic gland because of an increased risk of new-onset cancer.<sup>103–104</sup> In patients with MD-IPMN and those with mixed-type (MT)-IPMN several factors may predict progression during surveillance (eg, diffuse MPD dilatation, serum CA 19-9, serum alkaline phosphatase, and absence of extrapancreatic cysts).<sup>105–106</sup>

### 4.2 What are the clinical implications of the presence of potential risk factors, including morphological features, with regard to determining follow-up investigations, and the decision to proceed with surgical resection

*For patients with an IPMN without an indication for operative intervention, routine follow-up is recommended. A 6-month follow-up in the first year, and yearly follow-up thereafter is adequate when no risk factors are present that establish an indication for surgery. Changes in clinical symptoms should trigger investigations (GRADE 1B, strong agreement).*

*For patients with relative indication for surgery (see statement 4.12), the 'elderly', and those affected by severe comorbidity, a 6-month follow-up is recommended. (GRADE 1B, strong agreement).*

In young individuals, the risk of malignancy and surgery has to be balanced against the burden of lifelong follow-up.<sup>107</sup> However,

**Table 2** Risk of high-grade dysplasia or malignancy according to dilatation of the main pancreatic duct in IPMN

Reference	Study design	Number of patients	MPD dilatation	Patients with either high-grade dysplasia or malignancy (%)
Ogawa <i>et al</i> <sup>127</sup> 2008	Retrospective	61	$\geq 6$ mm	91
Shin <i>et al</i> <sup>128</sup> 2010	Retrospective	204	$\geq 6$ mm	30
Abdeljawad <i>et al</i> <sup>95</sup> 2014	Retrospective	52	$\geq 8$ mm	56
Hackert <i>et al</i> <sup>94</sup> 2015	Retrospective	320	$\geq 5$ mm	59
Seo <i>et al</i> <sup>93</sup> 2016	Retrospective	158	$\geq 5$ mm	49

MPD, main pancreatic duct.

after partial pancreatectomy for IPMN lifelong follow-up is still indicated. Resection therefore does not eliminate the need for regular follow-up screening.

**4.3 Is there a certain size cut-off point for resecting an IPMN regardless of the absence of clinical symptoms or (other) risk factors? Is age of the patient a co-factor that should be analysed to define better management strategy?**

*Patients with IPMNs >40 mm have an increased risk of harbouring malignancy (GRADE 1B, strong agreement).*

Several studies including both surgically resected or observed IPMN have reported an increased risk of malignancy ranging from 12% to 47% in cases of a cyst  $\geq 30$  mm.<sup>85 96 108–110</sup> In some of these series, the risk of malignancy produced by cyst size was stratified by the presence of other features for malignancy, indicating that cyst size alone is not an appropriate indication for surgery since the risk of malignancy is actual but low.<sup>92 111</sup> If multiple risk factors are present the sensitivity to detect malignancy increases.<sup>89 112</sup>

**4.4 What is the best imaging modality for the follow-up of IPMN?**  
*MRI is the preferred imaging modality for the follow-up of IPMN. EUS can be used in selected cases (GRADE 1B, strong agreement).*

See section 3 for details.

**4.5 Should the progress of IPMN be followed for as long as the patient is fit for surgery?**

*The risk of IPMN progression increases over the time, therefore patients affected by IPMN without indication for surgery should be followed up until they are no longer fit for surgery (GRADE 1B, strong agreement).*

The risk of progression of IPMN increases over the time as does the risk of developing indications for surgical resection. Interruption of surveillance is not recommended if the patient is fit for a potential surgical resection.<sup>107 113 114</sup> A single study on IPMN concluded that patients with a Charlson-age comorbidity index  $\geq 7$  have an 11-fold risk of comorbidity-related death within 3 years and only 6% of patients will die of malignant IPMN.<sup>115</sup>

**4.6 Should patients with IPMNs be screened for other tumours (including pancreatic cancer)?**

*The incidence of new extra-pancreatic neoplasms during the follow-up evaluation of pancreatic IPMN is not significantly greater than in the general population. Comprehensive screening outside the national protocols might not be necessary. Patients with IPMN are at risk of developing pancreatic cancer and attention should be paid to its concomitant development even when an IPMN has been successfully resected (GRADE 1C, strong agreement).*

A systematic review concluded that the available data remain inconclusive.<sup>116</sup> Two large studies including both surgically resected or followed IPMN did not find any difference in terms of incidence of extra-pancreatic neoplasms in patients with IPMN if compared with the general population.<sup>117 118</sup>

**4.7 Should MD-IPMN always be resected?**

*Patients with MD-IPMN who are fit for surgery should undergo resection (GRADE 1B, strong agreement).*

Surgery for MD-IPMN is universally accepted considering the high-rate of malignancy due to MD-IPMN,<sup>93 119</sup> even though no randomised trials comparing surgery with observation are available. As discussed in statement 4.1 above, a MD-IPMN

measuring between 5 and 9.9 mm is a relative indication for surgical resection, while MD-IPMN measuring  $\geq 10$  mm (see statement 4.1 for details) is an absolute indication for surgical resection.

**4.8 Should mixed-type (MT)-IPMN be managed in a similar manner to MD-IPMN?**

*MT-IPMN carries a risk of malignant transformation that is comparable to MD-IPMN, and resection is therefore advised in patients who are fit for surgery (GRADE 2C, strong agreement).*

Few studies have investigated MT-IPMN as a single entity. Malignancy rates appear similar for MT-IPMN and MD-IPMN.<sup>120</sup> Recently, a pathological classification distinguishing minimal (microscopic) and extensive (macroscopic) involvement of the MPD showed a significant difference in the risk of high-grade dysplasia or cancer (17% and 70% respectively).<sup>121</sup> However, this classification can be used only after resection, and is thus irrelevant for clinical assessment before surgery.

**4.9 What type of resection is indicated when the entire MPD is dilated on imaging?**

*Pancreatoduodenectomy with frozen section analysis of the resection margins is recommended for patients with MPD dilatation comprising the entire length of the pancreas (GRADE 2C, strong agreement).*

*In cases in which there is a mural nodule within the MPD further along the duct, or in patients with an increased risk for malignancy (ie, patients with familial pancreatic cancer), a total pancreatectomy can be considered (GRADE 2C, strong agreement).*

It is important to assess the MPD for a mural nodule before surgical exploration (see sections 2 and 3 for details). There are conflicting data and opinions about the extent of surgery for MD-IPMN.<sup>122</sup> Some authors advocate total pancreatectomy in every patient affected by MD-IPMN with radiological involvement of the entire MPD because of the relatively high-risk of high-grade dysplasia and cancer.<sup>123 124</sup> Others suggest total pancreatectomy only when there is a positive family history of pancreatic cancer,<sup>125</sup> or partial pancreatectomy followed by close surveillance, with completion pancreatectomy where progression or recurrence is suspected.<sup>126</sup> In this situation, pancreatoscopy may be useful to determine the extent of MPD involvement (see statement 3.7 for details). Where there is either a radiological suspicion, or histological proof of an IPMN-associated invasive carcinoma in the head of the pancreas, total pancreatectomy is not recommended, as the cancer will determine the prognosis.

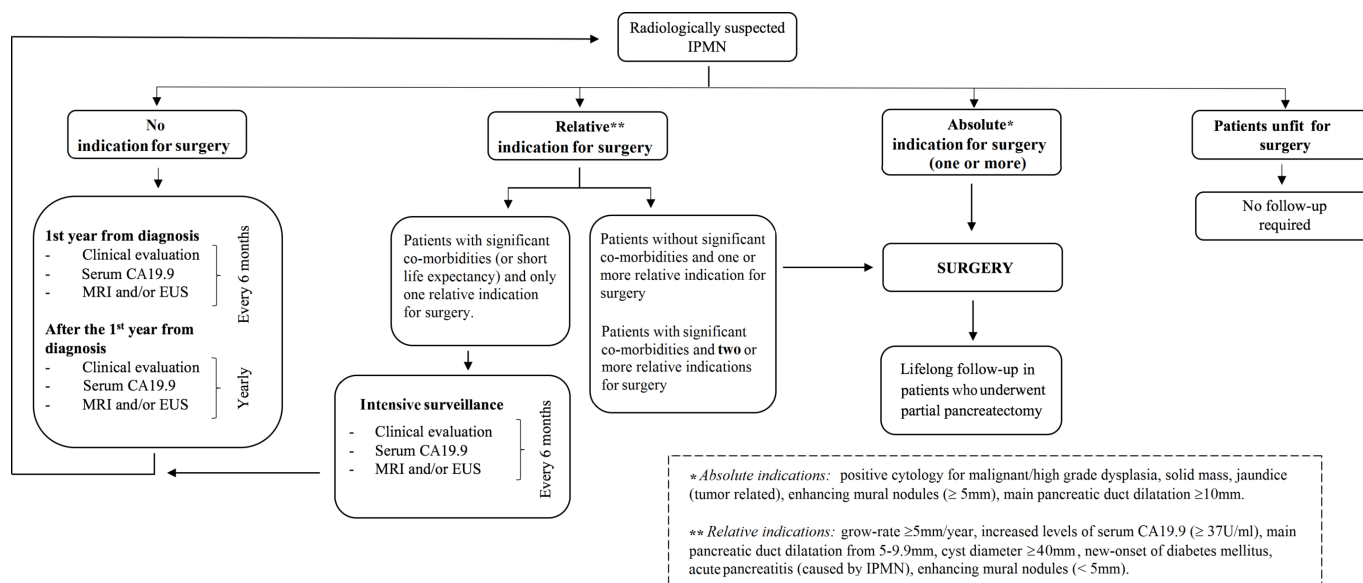
**4.10 At what MPD diameter should surgery be considered?**

*Recent studies demonstrate malignancy rates of 30–90% even in cases with a MPD dilatation of >5 mm.<sup>93–95 127–131</sup> Consequently, the threshold of MPD dilatation for surgical resection is >5 mm in both MD-IPMN and MT-IPMN (GRADE 2C, weak agreement).*

The main goal of surgery is to resect IPMNs when high-grade dysplasia is present, and before patients develop pancreatic cancer. Given the recent studies, and the goal of surgery, a cut-off point of >5 mm is reasonable (see figure 1).

**4.11 What are the absolute criteria for resection of BD-IPMN?**

*The presence of jaundice, cytology positive for high-grade dysplasia or cancer, the presence of a contrast-enhancing mural nodule ( $\geq 5$  mm) or solid mass should be considered as absolute indications for surgery (GRADE 1B, strong agreement).*



**Figure 1** Indications for surgery. EUS, endoscopic ultrasound; IPMN, intraductal papillary mucinous neoplasm.

See statements 4.1–4.2, for a detailed description of the rationale for this.

#### 4.12 Which are the relative criteria for resection of BD-IPMN?

Growth rate  $\geq 5$  mm/year, increased serum CA 19.9 level ( $> 37$  U/mL in the absence of jaundice), MPD diameter between 5 and 9.9 mm, cyst diameter  $\geq 40$  mm, symptoms (new-onset of diabetes mellitus or acute pancreatitis), and contrast-enhancing mural nodules  $< 5$  mm can be considered relative indications for surgical resection (GRADE 2C, strong agreement).

Table 3 shows absolute and relative indications for surgery.

CA 19.9 values in the serum  $> 37$  U/mL have been associated with a positive predictive value of 74.0% and accuracy of 81.7% to identify patients with invasive IPMN. Highly elevated levels of CA 19.9 may thus be helpful as an additional but not sole indicator for invasive IPMN.<sup>132</sup>

A recent large cohort of patients, who underwent surveillance for IPMN in accordance with the previous European expert statement, validates the safety of observation of BD-IPMN measuring  $< 40$  mm in the absence of other risk factors.<sup>107</sup> However, other data show that even small IPMN may develop into high-grade dysplasia or cancer. This highlights the importance of evaluating for the presence of multiple risk factors.<sup>88 133–135</sup> The greater the number of risk factors, the higher the probability of

malignancy.<sup>136 137</sup> Table 4 shows the risk of high-grade dysplasia or malignancy according to cyst size in BD-IPMN.

#### 4.13 Which kind of surgery should be performed for patients with BD-IPMN?

The surgical approach for most BD-IPMN is an oncological resection with standard lymphadenectomy. Parenchyma-sparing pancreatectomy (PSP) is a non-oncological procedure, which is suitable only for lesions with a very low probability of malignancy—for example in patients without risk factors who have a strong wish to be operated on (GRADE 2C, strong agreement).

Considering that surgery is indicated only for lesions with a potential risk of cancer or high-grade dysplasia, the indications for PSP are very limited. Diagnostic use of these procedures is reported occasionally in patients at increased risk of malignancy (ie, familial pancreatic cancer).<sup>138</sup> Since the morbidity of PSP is the same as that of conventional pancreatectomies, the advantage of performing PSP over conventional pancreatectomy is unclear.<sup>139 140</sup>

#### 4.14 When is full lymph node dissection required?

An oncologic resection including standard lymphadenectomy is the preferred procedure for IPMN with an absolute indication for resection<sup>141 142</sup> (GRADE 1C, strong agreement).

#### 4.15 How should multifocal BD-IPMN be evaluated for surgery? Is it safe to leave in place BD-IPMN without clinical or radiological signs of high-grade dysplasia or cancer when resecting another part of the pancreas?

In multifocal BD-IPMN, each cyst should be evaluated individually for the presence of features associated with malignancy. Cysts without concerning features can undergo surveillance<sup>143–148</sup> (GRADE 2C, strong agreement).

In cases of multifocal IPMN each lesion should be evaluated for surgical resection as a single entity according to the criteria reported in statements 4.10–4.11. Once this appraisal is performed, a tailored surgical approach can be planned. An intraoperative analysis of the surgical margins may help to determine the need for expanded resection.<sup>145 149</sup>

**Table 3** Absolute and relative indications for surgery in IPMN

Absolute indications	Relative indications
Positive cytology for malignancy/HGD	Grow-rate $\geq 5$ mm/year
Solid mass	Increased levels of serum CA 19.9 ( $> 37$ U/mL)*
Jaundice (tumour related)	MPD dilatation between 5 and 9.9 mm
Enhancing mural nodule ( $\geq 5$ mm)	Cyst diameter $\geq 40$ mm
MPD dilatation $\geq 10$ mm	New onset of diabetes mellitus
	Acute pancreatitis (caused by IPMN)
	Enhancing mural nodule ( $< 5$ mm)

\*In the absence of jaundice.

HGD, high-grade dysplasia; IPMN, intraductal papillary mucinous neoplasm; MPD, main pancreatic duct.



**Table 4** Risk of high-grade dysplasia or malignancy according to cyst size in branch duct IPMN

Reference	Study design	Number of patients	Cyst size	Patients with either high-grade dysplasia or malignancy (%)
Woo <i>et al</i> <sup>109</sup> 2009	Retrospective	190	>30 mm	28.5%
Sadakari <i>et al</i> <sup>110</sup> 2010	Retrospective	73	>30 mm	3.6% 26.3% (if MPD>5 mm)
Ohtsuka <i>et al</i> <sup>143</sup> 2012	Retrospective	172	>30 mm	29.2%
Hirono <i>et al</i> <sup>96</sup> 2012	Retrospective	134	>30 mm	47.4%
Sahora <i>et al</i> <sup>85</sup> 2013	Retrospective	240	>30 mm	12%
Masica <i>et al</i> , 2017	Retrospective	584	>40 mm	88% sensitivity 40% specificity

IPMN, intraductal papillary mucinous neoplasm; MPD, main pancreatic duct.

#### 4.16 Should frozen section analysis be performed routinely in IPMN undergoing surgical resection?

*Frozen section analysis of the pancreatic resection margin should be performed for all partial pancreatectomies and PSP in patients with IPMN (GRADE 1C, strong agreement).*

Although frozen section analysis is recommended, data on its clinical impact on the resection margin of an IPMN undergoing surgical resection are contradictory.<sup>126 149–164</sup>

#### 4.17 How will the frozen section result alter the surgical procedure?

*If high-grade dysplasia or cancer is present at the surgical margin, further resection is warranted, up to a total pancreatectomy. In contrast, the presence of lower grades of dysplasia may not require any further resection (GRADE 2C, strong agreement).*

Extending the resection may be considered in young fit patients, especially those at an increased risk for cancer (ie, familial pancreatic cancer), with low-grade dysplasia at the resection margin. Frozen section analysis is useful for detecting microscopic spread of cancerous lesions but is unable to detect the presence of discontinuous (skip) lesions, which occur in 6–42% of cases.<sup>165–167</sup> Moreover, detailed observation of the remnant MPD using intraoperative pancreatoscopy may provide identification of preoperatively undetected lesions.<sup>80 168 169</sup> Patients should always be counselled about the potential need for a total pancreatectomy.

#### 4.18 What is the value of the frozen section in resected IPMN with cancer?

*Frozen section examination of the pancreas resection margin should be performed in patients with an IPMN and cancer. In cases with a resection margin, which on frozen section is positive for pancreatic cancer, it is strongly recommended that the resection is extended. In cases of high-grade dysplasia at the resection margin, extension of the resection should be considered. No extension of the resection margin is indicated for low-grade dysplasia (GRADE 2C, strong agreement).*

Data vary on the value of a positive frozen section to predict IPMN cancer recurrence after surgery.<sup>126 149 150 154–157 159 161 170 171</sup> An IPMN associated with invasive carcinoma, with no lymph node metastases, appears to be associated with a better long-term outcome than pancreatic cancer.<sup>172</sup> For this reason, extension of the resection margin in cases of cancer or high-grade dysplasia appears reasonable in these patients.

#### 4.19 How are surgical outcomes affected by cyst location, comorbidity, patient age, and how should these features be weighted?

*The surgical strategy should be individualised for each patient, based on the type of surgical resection, the patients' age,*

*comorbidities, and the patient's preference (GRADE 2C, strong agreement).*

A more conservative approach may be considered for IPMN located in the head of the pancreas in elderly patients or patients with multiple comorbidities.<sup>100 107 173</sup> However, this conservative approach should be weighted with the potential risk of progression<sup>107</sup> or development of high-grade dysplasia or cancer.<sup>174</sup>

#### 4.20 How should patients be followed up who underwent surgical resection for an IPMN?

*Lifelong surveillance is recommended following resection of an IPMN as long as the patient is fit and is willing to undergo surgery if indicated. Patients with evidence of an IPMN-associated invasive carcinoma should be followed up in the same manner as those with a resected pancreatic cancer. IPMN with high-grade dysplasia or MD-IPMN should have close follow-up every 6 months for the first 2 years, followed by yearly surveillance. IPMN with low-grade dysplasia should be followed up in the same manner as non-resected IPMN (see statement 4.2 and figure 1 for details). Patients with IPMN in the remnant pancreas, who do not have high-grade dysplasia or MD-IPMN, should be followed up in the same manner as non-resected BD-IPMN (see section 4.15 and figure 1 for details). Follow-up imaging using MRI or EUS is recommended (GRADE 2C, strong agreement).*

Several studies have reported that IPMN recurrence is possible 5 to 10 years after resection.<sup>175 176</sup> The risk of BD-IPMN and MD-IPMN recurrence is similar (7–8%).<sup>161</sup> Resected IPMN with low-grade dysplasia have a low risk of recurrence (5.4–10%) with disease-free survival of approximately 52 months, while IPMN with high-grade dysplasia or an IPMN-associated invasive carcinoma have a higher risk (>50%), with disease-free survival of 29 months.<sup>85 161</sup>

#### 4.21 What preoperative investigation should be performed for a patient with an IPMN-associated invasive carcinoma? Should the same criteria be used as for pancreatic cancer?

*The diagnostic investigation for an IPMN-associated invasive cancer should follow the same algorithm used for pancreatic cancer.<sup>177</sup> (GRADE 1C, strong agreement).*

No studies have examined the differences between an IPMN-associated invasive carcinoma and spontaneous pancreatic cancer with respect to local tumour extension or staging for distant metastases.

#### 4.22 Should patients with an IPMN and a family history of pancreatic cancer be managed in a similar manner to patients with an IPMN but no family history?

*We recommend that the management of asymptomatic patients with an IPMN and a positive family history of pancreatic cancer*

is the same as that of patients with a sporadic IPMN (GRADE 2C, weak agreement).

There is no reported evidence that IPMN occurring in patients with a family history of pancreatic cancer have more rapid progression to high-grade dysplasia or cancer than sporadic cases.<sup>178–181</sup>

#### 4.23 Should patients who have undergone an organ transplant, and have an IPMN be managed in the same way as non-transplanted patients with IPMN?

We recommend that surveillance of patients who have undergone an organ transplant and have an IPMN should be the same as for non-transplanted patients<sup>182–186</sup> (GRADE 1B, strong agreement).

#### 4.24 Should patients who have an IPMN which fulfils criteria for surgical resection but who are not surgical candidates be treated with ablative techniques?

Further studies are required to clarify the indications for, and safety of, EUS-guided ablative injection techniques (ethanol, paclitaxel), radiofrequency ablation, or cryoablation for treatment of IPMNs. These should not be performed outside of clinical trials approved by the institutional review board (GRADE 1C, strong agreement).

EUS ablative procedures for the treatment of IPMN are not standardised and their efficacy is unclear. Furthermore, there is a lack of reliable markers to indicate successful and complete ablation.<sup>187–191</sup>

### 5 Mucinous cystic neoplasm

#### 5.1 Should patients with MCN always undergo surgical resection?

MCN  $\geq 40$  mm should undergo surgical resection. Resection is also recommended for MCN which are symptomatic or have risk factors (ie, mural nodule) irrespective of their size<sup>192</sup> (GRADE 1B, strong agreement).

The rate at which the size of an MCN increases should be considered. Some case reports have suggested considerably faster growth of MCN during pregnancy, potentially leading to tumour rupture.<sup>193</sup> Therefore, patients with MCN should be observed closely during pregnancy.

#### 5.2 Is it safe to follow up presumed MCN, which measures $<40$ mm?

It is safe to follow up presumed MCN that measure  $<40$  mm, in the absence of risk features such as a suspicious mural nodule or symptoms<sup>192</sup> (GRADE 2C, strong agreement).

For patients with MCN measuring between 30 and 40 mm, clinicians can incorporate other factors such as age, comorbidities, patient's surgical risk, and patient preference. For cysts measuring  $<30$  mm, it may be difficult to make a definitive diagnosis of an MCN, and smaller MCN may sometimes be difficult to distinguish from other cystic lesions. We therefore recommend similar surveillance for MCN and IPMN measuring  $<3$  cm.

#### 5.3 How should MCN, which is not resected, be followed up?

MCN measuring  $<40$  mm without a mural nodule or symptoms may undergo surveillance with MRI, EUS, or a combination of both.<sup>7 194</sup> Surveillance is recommended every 6 months for the first year, then annually if no changes are observed. Patients with an MCN measuring  $<40$  mm and with no concerning features or symptoms should have lifelong surveillance as long as they are fit for surgery (GRADE 2C, strong agreement).

Earlier studies have evaluated features associated with malignant transformation for all mucinous lesions combined. However, IPMNs and MCN may have different rates of growth

and malignant transformation and different features predictive of malignancy.<sup>195</sup>

#### 5.4 Is cyst fluid analysis recommended for MCN?

See statement 3.3.

#### 5.5 Which surgical procedure(s) should be performed for an MCN?

To avoid incomplete treatment of invasive carcinoma, a standard oncologic resection (distal pancreatectomy in 90–95% of MCN) with lymph node dissection and splenectomy is indicated for any MCN with imaging features indicating high-grade dysplasia or cancer (GRADE 1B, strong agreement).

MCN without suspect features with a low risk of malignancy can be treated with a non-oncological resection (distal pancreatectomy with splenic preservation with or without preservation of splenic vessels, or PSP) (GRADE 2C, strong agreement).

A PSP may be considered in selected patients to decrease the long-term risk of diabetes, provided the anatomical location is favourable (GRADE 2C, strong agreement).

PSP are associated with higher early morbidity and longer hospitalisation.<sup>139 140 196</sup> A laparoscopic approach is feasible for MCN. Its benefit over an open approach is comparable to other indications.<sup>197</sup>

### 6 Serous cystic neoplasm

#### 6.1 Does malignant SCN exist? is there a risk of malignant transformation?

SCN is a benign entity. There are essentially no deaths that are attributable to dissemination/malignant behaviour of an SCN. Specific mortality due to an SCN is nearly zero<sup>198 199</sup> (GRADE 2C, strong agreement).

Cases reported as 'malignant'<sup>200–202</sup> do not fulfil the WHO criteria for an SCN.

#### 6.2 If there is a clear diagnosis of an SCN, can follow-up be discontinued?

Asymptomatic patients with radiological evidence of an SCN should be followed up for 1 year. After 1 year, symptom-based follow-up is recommended (GRADE 2C, strong agreement).

#### 6.3 When does a possible SCN require follow-up?

Only when the diagnosis is uncertain is follow-up required. In these cases, a patient should undergo the same follow-up as for a BD-IPMN (see section 4.15, and figure 1 for details) (GRADE 2C, strong agreement).

#### 6.4 When does a SCN require surgery and which procedure should be performed?

When the diagnosis of SCN is clear, surgery is recommended only in patients with symptoms related to the compression of adjacent organs (ie, bile duct, stomach, duodenum, portal vein) (GRADE 2C, strong agreement).

The size of about 60% of SCN remains stable. An increase in cyst size is seen in 40% but the rate of growth is slow and new onset of symptoms is very rare.<sup>198 203–211</sup>

### 7 Other uncommon and undefined cystic tumours of the pancreas

#### 7.1 When the diagnosis of a cyst is unclear based on a specific imaging modality, should other investigations always be undertaken?

For a cyst measuring  $<15$  mm, either cross-sectional imaging or EUS alone may be performed.<sup>212</sup>



For cysts  $\geq 15$  mm, or if the diagnosis is unclear, both cross-sectional imaging and EUS should be performed, including EUS-FNA if warranted.

## 7.2 How should a small, undefined cyst be followed up?

*Cysts which are of unclear aetiology, have no risk factors for malignancy, and measure  $< 15$  mm, should be re-examined after 1 year. If stable for 3 years, follow-up may be extended to every 2 years.<sup>209</sup> Cysts measuring  $\geq 15$  mm should be followed up every 6 months during the first year and annually thereafter<sup>107</sup> (GRADE 2C, strong agreement).*

As an undefined cyst may be mucinous by nature, surveillance is recommended.<sup>85 107</sup> Most studies report that the risk of malignant transformation of PCN increases with size. This probably also applies to cysts of unclear aetiology.

A prospective population-based study found that unidentified cysts are very common (49% when including diameters of  $\geq 2$  mm), increase in number and size with age of the population (57% of subjects), but have no effect on pancreatic disease-associated mortality over 5 years.<sup>32</sup>

Recommendations that include 6-month surveillance intervals may therefore constitute overtreatment in cases where IPMN and MCN have been ruled out.

## 7.3 Duration of follow-up of undefined cysts

*Patients with undefined cysts should undergo lifelong follow-up, unless the patient is unwilling, or unfit to undergo pancreatic surgery (GRADE 2C, strong agreement).*

The long-term evolution of PCN is still largely unknown, which also applies to undefined pancreatic cysts. Therefore, no rational term for termination of surveillance can be given. However, recent data suggest that the risk of progression increases over time.<sup>107</sup>

## 7.4 Should all solid-pseudopapillary neoplasms (SPN) be resected?

*Radical resection should be performed for all SPN (GRADE 1B, strong agreement).*

Even in the absence of a large series, the surgical resection of SPN is internationally recommended and associated with positive long-term outcome.<sup>213 214</sup>

## 7.5 Can locally advanced SPN be resected? Should synchronous or metachronous metastases be resected?

*In cases of locally advanced, metastatic or recurrent SPNs, an aggressive surgical approach, with complete resection is indicated (GRADE 2C, strong agreement).*

SPNs are rare, and there is a lack of high-quality studies to guide care. Most studies are small, retrospective case series, making comparison between studies difficult.<sup>215–217</sup>

## 7.6 How is the diagnosis of a cystic pancreatic neuroendocrine tumour (PNEN) established?

*A definitive diagnosis of a cystic PNEN can be established only by histological examination. A preoperative diagnosis is often suspected based on particular features of cross-sectional imaging, and can be confirmed by EUS-guided cytology (GRADE 2C, strong agreement).*

Cystic PNEN often have a peripheral hypervascular rim visible on an arterial phase CT scan.<sup>218–220</sup> However, SCN may have a similar appearance, hampering differentiation. Data on functional imaging with Octreoscan, or Gallium Octreotate positron emission tomography in cystic PNEN are limited.

## 7.7 What are the indications to resect cystic PNEN and which procedures are recommended?

*For cystic PNEN  $> 20$  mm, surgery is recommended (pancreato-duodenectomy, distal pancreatectomy, or enucleation (including lymphadenectomy), according to tumour localisation).*

*For asymptomatic cystic PNEN  $\leq 2$  cm, in the absence of signs of malignant behaviour, surveillance is recommended (GRADE 2C, strong agreement).*

A recent meta-analysis concluded that cystic PNENs tend to be biologically less aggressive than their solid counterparts. Despite this, cystic PNENs have an approximately 20% risk of malignancy, with a 5-year overall survival of 87–100%.<sup>221</sup> A small tumour diameter is a favourable prognostic factor among PNENs. Therefore, small cystic PNENs  $\leq 20$  mm may be considered as indolent tumours with a small risk of malignant transformation<sup>222</sup> and an observational strategy has been suggested in the absence of symptoms.

## 7.8 Which are the rare cystic pancreatic lesions? When should they be considered and how is the diagnosis established?

*Rare cystic pancreatic lesions include hydatid cysts, haemangioma, lymphoepithelial cysts, acinar cell cystadenomas, desmoid cysts, and haemolymphangiomas.<sup>223–229</sup> Such cysts require a multidisciplinary approach, in an expert pancreatic centre, to determine the optimum management strategy. Surgery may be necessary if the diagnosis remains unclear (GRADE 2C, strong agreement).*

## 8 Adjuvant and neoadjuvant treatment

### 8.1 Is adjuvant treatment recommended for resected IPMN or MCN with associated invasive carcinoma? if yes, what is the optimal regimen?

*Adjuvant systemic chemotherapy is recommended for IPMN with an associated invasive carcinoma with or without positive lymph node status, as they have more aggressive biological behaviour<sup>165 230–239</sup> (GRADE 1C, strong agreement).*

As for patients with pancreatic cancer, adjuvant treatment can also be recommended for patients without lymph node involvement, but there is no scientific evidence to support this. *Adjuvant treatment of MCN-associated invasive carcinoma is similar to sporadic pancreatic adenocarcinoma, although no evidence is available to support or refute this approach (GRADE 2C, strong agreement).*

*No specific recommendation can be given for which chemotherapy agent should be used, as there is substantial heterogeneity among studies. The most commonly used drugs are 5-fluorouracil and gemcitabine, similar to adjuvant treatment of pancreatic adenocarcinoma (GRADE 2C, strong agreement).*

### 8.2 Is neoadjuvant treatment recommended for locally advanced carcinoma associated with an IPMN or MCN?

*No recommendation can be made for neoadjuvant treatment of locally advanced IPMN- or MCN-associated invasive carcinoma, as there are insufficient data<sup>240–243</sup> (GRADE 2C, strong agreement).*

Two case reports have been published, supporting the use of preoperative chemotherapy for IPMN and MCN.<sup>244 245</sup> An approach similar to that used for patients with pancreatic cancer can be considered, given the similarities between the two diseases.

### 8.3 Is adjuvant or neoadjuvant treatment indicated for SPN? If yes, what is the optimum regimen?

*Neoadjuvant therapy for SPN is not routinely recommended, as there are no studies proving its efficacy (GRADE 2C, strong agreement).*

The only data for neoadjuvant or adjuvant therapy for SPN are from case reports, the majority of which report different chemotherapy regimens, and many of which were used in a palliative setting after postsurgical recurrence.<sup>246–252</sup>

#### 8.4 Is palliative chemotherapy recommended for non-resectable or recurrent malignant cystic tumours of the pancreas?

*Systemic palliative chemotherapy for non-resectable or recurrent malignant cystic tumours may be considered as for pancreatic adenocarcinoma, although there is no evidence available to support or refute this approach.*<sup>230 253 254</sup> (GRADE 2C, strong agreement).

Given the similarity to pancreatic cancer, palliative chemotherapy may be considered for patients with non-resectable, recurrent, or metastatic disease occurring in the setting of a malignant IPMN or MCN, analogous to pancreatic cancer.

#### 8.5 Is surgical resection of metastases, or recurrence of an IPMN or MCN cancer justified?

*Surgical resection of metastasis, or local recurrence cannot be recommended because there are no studies evaluating this* (GRADE 2C, strong agreement).

### 9 Pathology

#### 9.1 How should PCN surgical specimens be examined?

##### *Specimen dissection*

*Axial specimen slicing is the standard in an increasing number of European countries and pancreatic centres.*<sup>255 256</sup> (GRADE 2C, strong agreement).

No studies have been published on the optimal grossing of pancreatic resection specimens with cystic lesions.

##### *Macroscopic examination*

*Size, uni-/multilocularity, wall thickness, solid areas/mural nodules, cyst content, relationship to the duct system, and appearance of the background pancreas should be documented. In the case of macroscopically visible invasive carcinoma, a full macroscopic description is required, similar to that documented in ductal adenocarcinoma. The spatial relationship and distance of the cancer from the cystic lesion should be recorded.*<sup>257 258</sup> (GRADE 2C, strong agreement).

##### *Tissue sampling*

*Extensive sampling is paramount to establish an accurate diagnosis. Sampling of the resection margins should be conducted as recommended for pancreatic specimens resected for pancreatic ductal adenocarcinoma* (GRADE 2C, strong agreement).

The minimum number of tissue samples that should be taken to ensure accurate diagnosis has not been established for PCN.

#### 9.2 How should surgical specimens with an IPMN lesion be examined and reported?

##### *Gross examination*

See statement 1.1. *Involvement of the MPD and/or branch duct(s), the length of the MPD that is macroscopically involved, and the largest diameter of the dilated MPD or of the cyst, in cases of BD-IPMNs, should be recorded. In cases of multifocal BD-IPMNs, the largest diameter of each lesion should be reported.*<sup>257</sup> (GRADE 2C, strong agreement).

##### *Histopathological examination*

*IPMN without an invasive carcinoma: the histological subtype should be documented (gastric, intestinal, pancreatobiliary or*

*oncocytic), based on morphology and immunohistochemical staining.*<sup>259 260</sup> For grading of dysplasia in an IPMN, the use of a two-tiered classification system (low-grade vs high-grade dysplasia) is recommended.<sup>258</sup> (GRADE 2C, strong agreement). *IPMNs with associated invasive carcinoma: the largest diameter of the invasive lesion should be measured and reported, in addition to the overall size of the lesion. The associated invasive carcinoma should be reported according to the WHO and Union for International Cancer Control (UICC) recommendations.*<sup>261</sup> If transition from an IPMN to invasive carcinoma is not demonstrable, complete sampling of the intervening tissues should be conducted to substantiate whether the IPMN and invasive carcinoma are truly separate.<sup>258</sup> (GRADE 2C, strong agreement).

The term 'malignant IPMN' should not be used. Instead, it should be simply stated whether invasion is present or not.<sup>257 258</sup> It is important to assess the histological subtype of IPMN, since it is associated with prediction of postoperative patient prognosis. The pancreatobiliary subtype, for example, is considered to be strongly associated with malignancy.<sup>262</sup>

#### 9.3 How to examine and report surgical specimens with an MCN?

##### *Gross examination*

See statement 9.1.

##### *Histopathological examination*

*The use of a two-tiered grading system for dysplasia (low vs high-grade) is recommended.*<sup>257</sup> The terms malignant MCN, invasive MCN, or mucinous cystadenocarcinoma should be abandoned and replaced by 'MCN with associated invasive carcinoma', according to the WHO and UICC recommendations.<sup>258 263</sup> (GRADE 2C, strong agreement)

#### 9.4 Use of potential molecular markers

See statement 1.1.

#### 9.5 Methodology for evaluation of cytology in PCN

*EUS-FNA is the preferred method for obtaining cytology in PCN. The preparation of the aspirated fluid may differ between laboratories: direct smears for thick mucus, cytospins, and liquid-based preparation for fluid material* (GRADE 2C, strong agreement).

Cytology for PCN has a low sensitivity but a high specificity (see statement 3.5).<sup>263</sup> Low sensitivity and frequent non-diagnostic yield are mainly due to low cellularity of the aspirated fluid.

#### 9.6 How to interpret and report PCN cytology

*A six-tiered classification system can be used.*<sup>259</sup> The mucinous or non-mucinous nature of a PCN and the degree of dysplasia are the most significant determinants of patient management.<sup>264 265</sup> (GRADE 2C, strong agreement).

International consensus on standardised terminology for pancreas cytology is lacking.

### DISCUSSION

The European evidence-based guidelines on PCN aim to improve the diagnosis and management of PCN. Eventually, the European Study Group on Cystic Tumours of the Pancreas strives to develop a global evidence-based guideline for PCN in a joint venture with the various national and international guideline groups, in order to harmonise care and to avoid confusion caused by conflicting statements. Future studies should deal with the optimal diagnosis (aetiology and neoplastic grade), appropriate selection criteria for surgery, surgical strategy (ie, partial

## Box 1 Current clinical dilemmas in pancreatic cystic neoplasms (PCN) and topics for future research

### Diagnostic investigation

- Which modality can most reliably distinguish neoplastic from non-neoplastic cysts (eg, imaging, needle-based confocal laser endomicroscopy, cyst fluid analysis, secretin-stimulated pancreatic juice collections)?
- Which modality can most reliably detect high-grade dysplasia or early cancer (neoplastic progression) in patients with PCN, to enable timely resection?

### Surgery

- What are absolute and relative (contra)indications for surgery in main duct (MD) and branch duct intraductal papillary mucinous neoplasm (BD-IPMN), especially in the subgroup 30–40 mm BD-IPMN?
- How extensive should a resection for MD-IPMN be (total vs partial pancreatectomy)?
- Is there a role for pre-/intraoperative pancreatoscopy to determine the extent of resection in MD-IPMN?
- What is the potential benefit of preventive surgery in relation to potential side effects, especially in patients with increased surgical risk or a limited life expectancy due to comorbidity?

### Surveillance

- What is a cost-effective and personalised approach to surveillance of (undefined) PCN?
- Which risk factors for progression need to be considered (eg, cyst size, smoking, diabetes mellitus, concurrent immunosuppression, familial pancreatic cancer history, other genetic syndromes)?
- What is the optimal modality and follow-up scheme for patients after a partial pancreatic resection for IPMN?

or total pancreatectomy), and follow-up strategy. Especially, identification of patients who do not require follow-up and may be discharged deserves further attention, as patient burden and societal costs of lifelong follow-up with cross-sectional imaging are substantial.

Compared with the recently updated Fukuoka guidelines,<sup>8</sup> this evidence-based guideline shows similar relative and absolute indications for surgery based on radiological findings. This guideline is, however, more conservative in the management of side-branch IPMN. Furthermore, new-onset diabetes mellitus is a relative indication for surgery, whereas this is not mentioned in the Fukuoka guidelines.

Also, a recent international survey revealed that consensus is lacking among international experts about the management of MT/MD-IPMN.<sup>122</sup> These dilemmas clearly demonstrate that future prospective, multicentre studies are required to provide the necessary evidence to guide management, see [box 1](#). The European study group supports the international multicentre PACYFIC study ([www.pacyfic.net](http://www.pacyfic.net)), an accessible cyst registry, which aims to obtain long-term follow-up of over 5000 people with an asymptomatic pancreatic cyst.

**Correction notice** This article has been corrected since it published Online First. Massimo Falconi has been added to the collaborator list.

**Acknowledgements** The European Study Group on Cystic Tumours of the Pancreas is grateful to the UEG, EPC, E-AHPBA, EDS, ESGE and Cancerfonden Sweden for their support and thanks Professor Patrick Bossuyt, Academic Medical Center Amsterdam for the methodological support.

**Collaborators** This guideline has been made possible by a large group of collaborators. These collaborators formed the writing committee, methodology

committee, nine review groups and the manuscript committee. The initial draft of the manuscript was written by Marco Del Chiaro (Karolinska) with the help of Lianne Scholten, Marc G Besselink (both AMC). The following collaborators were each involved in one or more of the committees and review groups (see supplementary material for details): Marco Del Chiaro, Marc G Besselink, Lianne Scholten, Marco J Bruno, Djuna L Cahen, Thomas M Gress, Jeanin E van Hooft, Markus M Lerch, Julia Mayerle, Thilo Hackert, Sohei Satoi, Alessandro Zerbi, David Cunningham, Claudio De Angelis, Marc Giovannini, Enrique de-Madaria, Peter Hegyi, Jonas Rosendahl, Helmut Friess, Riccardo Manfredi, Philippe Lévy, Francisco X Real, Alain Sauvanet, Mohammed Abu Hilal, Giovanni Marchegiani, Irene Esposito, Paula Ghaneh, Marc RW Engelbrecht, Paul Fockens, Nadine CM van Huijgevoort, Christopher Wolfgang, Claudio Bassi, Natalya B Gubergrits, Caroline Verbeke, Günter Klöppel, Aldo Scarpa, Giuseppe Zamboni, Anne Marie Lennon, Malin Sund, Nikolaos Kartalios, Lars Grenacher, Massimo Falconi, Urban Arnelo, Kostantin V Kopchak, Kofi Oppong, Colin McKay, Truls Hauge, Kevin Conlon, Mustapha Adham, Güralp O Ceyhan, Roberto Salvia, Christos Dervenis, Peter Allen, François Paye, Detlef K Bartsch, Matthias Löhr, Massimiliano Mutignani, Johanna Laukkanen, Richard Schulick, Roberto Valente, Thomas Seufferlein, Gabriele Capurso, Ajith Siriwardena, John P Neoptolemos, Aldis Pukitis, Ralf Segersvärd, A Aghdassi, S Andrianello, P Bossuyt, R Bülow, K Cárdenas-Jaén, P Cortegoso, M Fontana, L Haeberle, M Heckler, A Litvin, K Mann, C Michalski, P Michl, G Nappo, G Perri, S Persson, F Scheufele, F Sclafani, M Schmidt, L Venezia, F Volker, M-P Vulliam, and L Wüsten.

**Funding** The authors have not declared a specific grant for this research from any funding agency in the public, commercial or not-for-profit sectors.

**Competing interests** None declared.

**Patient consent** Not required.

**Provenance and peer review** Not commissioned; externally peer reviewed.

**Open Access** This is an Open Access article distributed in accordance with the Creative Commons Attribution Non Commercial (CC BY-NC 4.0) license, which permits others to distribute, remix, adapt, build upon this work non-commercially, and license their derivative works on different terms, provided the original work is properly cited and the use is non-commercial. See: <http://creativecommons.org/licenses/by-nc/4.0/>

© Article author(s) (or their employer(s) unless otherwise stated in the text of the article) 2018. All rights reserved. No commercial use is permitted unless otherwise expressly granted.

## REFERENCES

- 1 Ip IK, Mortele KJ, Prevedello LM, *et al*. Focal cystic pancreatic lesions: assessing variation in radiologists' management recommendations. *Radiology* 2011;259:136–41.
- 2 Girometti R, Intini S, Brondani G, *et al*. Incidental pancreatic cysts on 3D turbo spin echo magnetic resonance cholangiopancreatography: prevalence and relation with clinical and imaging features. *Abdom Imaging* 2011;36:196–205.
- 3 Chang YR, Park JK, Jang JY, *et al*. Incidental pancreatic cystic neoplasms in an asymptomatic healthy population of 21,745 individuals: large-scale, single-center cohort study. *Medicine (Baltimore)* 2016;95:e5535.
- 4 de Jong K, Nio CY, Hermans JJ, *et al*. High prevalence of pancreatic cysts detected by screening magnetic resonance imaging examinations. *Clin Gastroenterol Hepatol* 2010;8:806–11.
- 5 Del Chiaro M, Segersvärd R, Lohr M, *et al*. Early detection and prevention of pancreatic cancer: is it really possible today? *World J Gastroenterol* 2014;20:12118–31.
- 6 Del Chiaro M, Segersvärd R, Pozzi Mucelli R, *et al*. Comparison of preoperative conference-based diagnosis with histology of cystic tumors of the pancreas. *Ann Surg Oncol* 2014;21:1539–44.
- 7 Del Chiaro M, Verbeke C, Salvia R, *et al*. European experts consensus statement on cystic tumours of the pancreas. *Dig Liver Dis* 2013;45:703–11.
- 8 Tanaka M, Fernández-Del Castillo C, Kamisawa T, *et al*. Revisions of international consensus Fukuoka guidelines for the management of IPMN of the pancreas. *Pancreatology* 2017;17:738–53.
- 9 Vege SS, Ziring B, Jain R, *et al*. American Gastroenterological Association Institute guideline on the diagnosis and management of asymptomatic neoplastic pancreatic cysts. *Gastroenterology* 2015;148:819–22. quiz 12–3.
- 10 Jaeschke R, Guyatt GH, Dellinger P, *et al*. Use of GRADE grid to reach decisions on clinical practice guidelines when consensus is elusive. *BMJ* 2008;337:a744.
- 11 Atkins D, Best D, Briss PA, *et al*. Grading quality of evidence and strength of recommendations. *BMJ* 2004;328:1490.
- 12 Guyatt GH, Oxman AD, Vist GE, *et al*. GRADE: an emerging consensus on rating quality of evidence and strength of recommendations. *BMJ* 2008;336:924–6.
- 13 Hruban RH, Kloppel G, Bofetta P, *et al*. Tumours of the pancreas. In: Bosman FT, Carneiro F, Hruban RH, eds. *WHO classification of tumours of the digestive system*. 4th ed. Lyon: International Agency for Research on Cancer, 2010:280–330.



- 14 Jang JY, Park T, Lee S, *et al.* Proposed nomogram predicting the individual risk of malignancy in the patients with branch duct type intraductal papillary mucinous neoplasms of the pancreas. *Ann Surg* 2017;266:1062–8.
- 15 Wang W, Zhang L, Chen L, *et al.* Serum carcinoembryonic antigen and carbohydrate antigen 19-9 for prediction of malignancy and invasiveness in intraductal papillary mucinous neoplasms of the pancreas: a meta-analysis. *Biomed Rep* 2015;3:43–50.
- 16 Kim JR, Jang JY, Kang MJ, *et al.* Clinical implication of serum carcinoembryonic antigen and carbohydrate antigen 19-9 for the prediction of malignancy in intraductal papillary mucinous neoplasm of pancreas. *J Hepatobiliary Pancreat Sci* 2015;22:699–707.
- 17 Singhi AD, Nikiforova MN, Fasanella KE, *et al.* Preoperative GNAS and KRAS testing in the diagnosis of pancreatic mucinous cysts. *Clin Cancer Res* 2014;20:4381–9.
- 18 Springer S, Wang Y, Dal Molin M, *et al.* A combination of molecular markers and clinical features improve the classification of pancreatic cysts. *Gastroenterology* 2015;149:1501–10.
- 19 Singhi AD, Zeh HJ, Brand RE, *et al.* American Gastroenterological Association guidelines are inaccurate in detecting pancreatic cysts with advanced neoplasia: a clinicopathologic study of 225 patients with supporting molecular data. *Gastrointest Endosc* 2016;83:1107–17.
- 20 Kadayifci A, Atar M, Wang JL, *et al.* Value of adding GNAS testing to pancreatic cyst fluid KRAS and carcinoembryonic antigen analysis for the diagnosis of intraductal papillary mucinous neoplasms. *Dig Endosc* 2017;29:111–7.
- 21 Al-Rashdan A, Schmidt CM, Al-Haddad M, *et al.* Fluid analysis prior to surgical resection of suspected mucinous pancreatic cysts. A single centre experience. *J Gastrointest Oncol* 2011;2:208–14.
- 22 van der Waaij LA, van Dullemen HM, Porte RJ. Cyst fluid analysis in the differential diagnosis of pancreatic cystic lesions: a pooled analysis. *Gastrointest Endosc* 2005;62:383–9.
- 23 Jang DK, Song BJ, Ryu JK, *et al.* Preoperative diagnosis of pancreatic cystic lesions: the accuracy of endoscopic ultrasound and cross-sectional imaging. *Pancreas* 2015;44:1329–33.
- 24 Lee HJ, Kim MJ, Choi JY, *et al.* Relative accuracy of CT and MRI in the differentiation of benign from malignant pancreatic cystic lesions. *Clin Radiol* 2011;66:315–21.
- 25 Sainani NI, Saokar A, Deshpande V, *et al.* Comparative performance of MDCT and MRI with MR cholangiopancreatography in characterizing small pancreatic cysts. *AJR Am J Roentgenol* 2009;193:722–31.
- 26 Visser BC, Muthusamy VR, Yeh BM, *et al.* Diagnostic evaluation of cystic pancreatic lesions. *HPB (Oxford)* 2008;10:63–9.
- 27 Song SJ, Lee JM, Kim YJ, *et al.* Differentiation of intraductal papillary mucinous neoplasms from other pancreatic cystic masses: comparison of multirow-detector CT and MR imaging using ROC analysis. *J Magn Reson Imaging* 2007;26:86–93.
- 28 Laffan TA, Horton KM, Klein AP, *et al.* Prevalence of unsuspected pancreatic cysts on MDCT. *AJR Am J Roentgenol* 2008;191:802–7.
- 29 Spinelli KS, Fromwiller TE, Daniel RA, *et al.* Cystic pancreatic neoplasms: observe or operate. *Ann Surg* 2004;239:651–7.
- 30 Lee KS, Sekhar A, Rofsky NM, *et al.* Prevalence of incidental pancreatic cysts in the adult population on MR imaging. *Am J Gastroenterol* 2010;105:2079–84.
- 31 Zhang X-M, Mitchell DG, Dohke M, Holland GA, *et al.* Pancreatic cysts: depiction on single-shot fast spin-echo MR images. *Radiology* 2002;223:547–53.
- 32 Kromrey ML, Bülow R, Hübner J, *et al.* Prospective study on the incidence, prevalence and 5-year pancreatic-related mortality of pancreatic cysts in a population-based study. *Gut* 2018;67:138–45.
- 33 Sahani DV, Kambadakone A, Macari M, *et al.* Diagnosis and management of cystic pancreatic lesions. *AJR Am J Roentgenol* 2013;200:343–54.
- 34 Chaudhari VV, Raman SS, Vuong NL, *et al.* Pancreatic cystic lesions: discrimination accuracy based on clinical data and high resolution CT features. *J Comput Assist Tomogr* 2007;31:860–7.
- 35 de Jong K, Nio CY, Mearadji B, *et al.* Disappointing interobserver agreement among radiologists for a classifying diagnosis of pancreatic cysts using magnetic resonance imaging. *Pancreas* 2012;41:278–82.
- 36 Waters JA, Schmidt CM, Pinchot JW, *et al.* CT vs MRCP: optimal classification of IPMN type and extent. *J Gastrointest Surg* 2008;12:101–9.
- 37 Pilleul F, Rochette A, Partensky C, *et al.* Preoperative evaluation of intraductal papillary mucinous tumors performed by pancreatic magnetic resonance imaging and correlated with surgical and histopathologic findings. *J Magn Reson Imaging* 2005;21:237–44.
- 38 Berland LL, Silverman SG, Gore RM, *et al.* Managing incidental findings on abdominal CT: white paper of the ACR incidental findings committee. *J Am Coll Radiol* 2010;7:754–73.
- 39 Sodickson A, Baeyens PF, Andriole KP, *et al.* Recurrent CT, cumulative radiation exposure, and associated radiation-induced cancer risks from CT of adults. *Radiology* 2009;251:175–84.
- 40 Curry CA, Eng J, Horton KM, *et al.* CT of primary cystic pancreatic neoplasms: can CT be used for patient triage and treatment? *AJR Am J Roentgenol* 2000;175:99–103.
- 41 Demos TC, Posniak HV, Harmath C, *et al.* Cystic lesions of the pancreas. *AJR Am J Roentgenol* 2002;179:1375–88.
- 42 Pozzi-Mucelli RM, Rinta-Kiikka I, Wünsche K, *et al.* Pancreatic MRI for the surveillance of cystic neoplasms: comparison of a short with a comprehensive imaging protocol. *Eur Radiol* 2017;27:41–50.
- 43 Kartalis N, Lindholm TL, Aspelin P, *et al.* Diffusion-weighted magnetic resonance imaging of pancreas tumours. *Eur Radiol* 2009;19:1981–90.
- 44 Hwang J, Kim YK, Min JH, Jeong WK, *et al.* Comparison between MRI with MR cholangiopancreatography and endoscopic ultrasonography for differentiating malignant from benign mucinous neoplasms of the pancreas. *Eur Radiol* 2018;28:179–87.
- 45 Donahue TR, Hines OJ, Farrell JJ, *et al.* Cystic neoplasms of the pancreas: results of 114 cases. *Pancreas* 2010;39:1271–6.
- 46 Kim JH, Eun HW, Park HJ, *et al.* Diagnostic performance of MRI and EUS in the differentiation of benign from malignant pancreatic cyst and cyst communication with the main duct. *Eur J Radiol* 2012;81:2927–35.
- 47 Gress F, Gottlieb K, Cummings O, *et al.* Endoscopic ultrasound characteristics of mucinous cystic neoplasms of the pancreas. *Am J Gastroenterol* 2000;95:961–5.
- 48 Yamao K, Nakamura T, Suzuki T, *et al.* Endoscopic diagnosis and staging of mucinous cystic neoplasms and intraductal papillary-mucinous tumors. *J Hepatobiliary Pancreat Surg* 2003;10:142–6.
- 49 Ahmad NA, Kochman ML, Lewis JD, *et al.* Can EUS alone differentiate between malignant and benign cystic lesions of the pancreas? *Am J Gastroenterol* 2001;96:3295–300.
- 50 Ahmad NA, Kochman ML, Brensinger C, *et al.* Interobserver agreement among endosonographers for the diagnosis of neoplastic versus non-neoplastic pancreatic cystic lesions. *Gastrointest Endosc* 2003;58:59–64.
- 51 Kamata K, Kitano M, Omoto S, *et al.* Contrast-enhanced harmonic endoscopic ultrasonography for differential diagnosis of pancreatic cysts. *Endoscopy* 2016;48:35–41.
- 52 Harima H, Kaino S, Shinoda S, *et al.* Differential diagnosis of benign and malignant branch duct intraductal papillary mucinous neoplasm using contrast-enhanced endoscopic ultrasonography. *World J Gastroenterol* 2015;21:6252–60.
- 53 Fusaroli P, Kyraios D, Mancino MG, *et al.* Interobserver agreement in contrast harmonic endoscopic ultrasound. *J Gastroenterol Hepatol* 2012;27:1063–9.
- 54 de Jong K, van Hooft JE, Nio CY, *et al.* Accuracy of preoperative workup in a prospective series of surgically resected cystic pancreatic lesions. *Scand J Gastroenterol* 2012;47:1056–63.
- 55 Ardengh JC, Lopes CV, de Lima-Filho ER, *et al.* Impact of endoscopic ultrasound-guided fine-needle aspiration on incidental pancreatic cysts. A prospective study. *Scand J Gastroenterol* 2014;49:114–20.
- 56 Gillis A, Cipollone I, Cousins G, *et al.* Does EUS-FNA molecular analysis carry additional value when compared to cytology in the diagnosis of pancreatic cystic neoplasm? A systematic review. *HPB (Oxford)* 2015;17:377–86.
- 57 Al-Haddad M, DeWitt J, Sherman S, *et al.* Performance characteristics of molecular (DNA) analysis for the diagnosis of mucinous pancreatic cysts. *Gastrointest Endosc* 2014;79:79–87.
- 58 Brugge WR, Lewandrowski K, Lee-Lewandrowski E, *et al.* Diagnosis of pancreatic cystic neoplasms: a report of the cooperative pancreatic cyst study. *Gastroenterology* 2004;126:1330–6.
- 59 Cizginer S, Turner BG, Turner B, Bilge AR, *et al.* Cyst fluid carcinoembryonic antigen is an accurate diagnostic marker of pancreatic mucinous cysts. *Pancreas* 2011;40:1024–8.
- 60 Gaddam S, Ge PS, Keach JW, *et al.* Suboptimal accuracy of carcinoembryonic antigen in differentiation of mucinous and nonmucinous pancreatic cysts: results of a large multicenter study. *Gastrointest Endosc* 2015;82:1060–9.
- 61 Jin DX SA, Vollmer CM, Jhala N, *et al.* A lower cyst fluid CEA cut-off increases diagnostic accuracy in identifying mucinous pancreatic cystic lesions. *J Pancreas* 2015;16:271–7.
- 62 Kadayifci A, Al-Haddad M, Atar M, *et al.* The value of KRAS mutation testing with CEA for the diagnosis of pancreatic mucinous cysts. *Endosc Int Open* 2016;4:E391–6.
- 63 Khalid A, Zahid M, Finkelstein SD, *et al.* Pancreatic cyst fluid DNA analysis in evaluating pancreatic cysts: a report of the PANDA study. *Gastrointest Endosc* 2009;69:1095–102.
- 64 Winner M, Sethi A, Poneris JM, *et al.* The role of molecular analysis in the diagnosis and surveillance of pancreatic cystic neoplasms. *JOP* 2015;16:143–9.
- 65 Ngamruengphong S, Bartel MJ, Raimondo M. Cyst carcinoembryonic antigen in differentiating pancreatic cysts: a meta-analysis. *Dig Liver Dis* 2013;45:920–6.
- 66 Sedlack R, Affi A, Vazquez-Sequeiros E, *et al.* Utility of EUS in the evaluation of cystic pancreatic lesions. *Gastrointest Endosc* 2002;56:543–7.
- 67 Koito K, Namieno T, Nagakawa T, *et al.* Solitary cystic tumor of the pancreas: EUS-pathologic correlation. *Gastrointest Endosc* 1997;45:268–76.
- 68 Morris-Stiff G, Lentz G, Chalikhonda S, *et al.* Pancreatic cyst aspiration analysis for cystic neoplasms: mucin or carcinoembryonic antigen—which is better? *Surgery* 2010;148:638–45. discussion 44–5.
- 69 Tarantino I, Fabbri C, Di Mitri R, *et al.* Complications of endoscopic ultrasound fine needle aspiration on pancreatic cystic lesions: final results from a large prospective multicenter study. *Dig Liver Dis* 2014;46:41–4.

- 70 Barresi L, Tarantino I, Traina M, *et al.* Endoscopic ultrasound-guided fine needle aspiration and biopsy using a 22-gauge needle with side fenestration in pancreatic cystic lesions. *Dig Liver Dis* 2014;46:45–50.
- 71 Al-Haddad M, Wallace MB, Woodward TA, *et al.* The safety of fine-needle aspiration guided by endoscopic ultrasound: a prospective study. *Endoscopy* 2008;40:204–8.
- 72 Lee LS, Saltzman JR, Bounds BC, *et al.* EUS-guided fine needle aspiration of pancreatic cysts: a retrospective analysis of complications and their predictors. *Clin Gastroenterol Hepatol* 2005;3:231–6.
- 73 Varadarajulu S, Eloubeidi MA. Frequency and significance of acute intracystic hemorrhage during EUS-FNA of cystic lesions of the pancreas. *Gastrointest Endosc* 2004;60:631–5.
- 74 O'Toole D, Palazzo L, Arotçarena R, *et al.* Assessment of complications of EUS-guided fine-needle aspiration. *Gastrointest Endosc* 2001;53:470–4.
- 75 Bournet B, Miguères I, Delacroix M, *et al.* Early morbidity of endoscopic ultrasound: 13 years' experience at a referral center. *Endoscopy* 2006;38:349–54.
- 76 Guarner-Argente C, Shah P, Buchner A, *et al.* Use of antimicrobials for EUS-guided FNA of pancreatic cysts: a retrospective, comparative analysis. *Gastrointest Endosc* 2011;74:81–6.
- 77 Suzuki R, Thosani N, Annangi S, *et al.* Diagnostic yield of EUS-FNA-based cytology distinguishing malignant and benign IPMNs: a systematic review and meta-analysis. *Pancreatol* 2014;14:380–4.
- 78 Sieh M, Tripp K, Schmidt-Rohlfing B, *et al.* Cystic tumours of the pancreas: diagnostic accuracy, pathologic observations and surgical consequences. *Langenbecks Arch Surg* 1998;383:56–61.
- 79 Hara T, Yamaguchi T, Ishihara T, *et al.* Diagnosis and patient management of intraductal papillary-mucinous tumor of the pancreas by using peroral pancreatoscopy and intraductal ultrasonography. *Gastroenterology* 2002;122:34–43.
- 80 Navez J, Hubert C, Gigot JF, *et al.* Impact of intraoperative pancreatoscopy with intraductal biopsies on surgical management of intraductal papillary mucinous neoplasm of the pancreas. *J Am Coll Surg* 2015;221:982–7.
- 81 Konda VJ, Meining A, Jamil LH, *et al.* A pilot study of in vivo identification of pancreatic cystic neoplasms with needle-based confocal laser endomicroscopy under endosonographic guidance. *Endoscopy* 2013;45:1006–13.
- 82 Nakai Y, Iwashita T, Park DH, *et al.* Diagnosis of pancreatic cysts: EUS-guided, through-the-needle confocal laser-induced endomicroscopy and cystoscopy trial: DETECT study. *Gastrointest Endosc* 2015;81:1204–14.
- 83 Le Pen C, Palazzo L, Napoléon B. A health economic evaluation of needle-based confocal laser endomicroscopy for the diagnosis of pancreatic cysts. *Endosc Int Open* 2017;5:E987–95.
- 84 Napoléon B, Lemaistre AI, Pujol B, *et al.* A novel approach to the diagnosis of pancreatic serous cystadenoma: needle-based confocal laser endomicroscopy. *Endoscopy* 2015;47:26–32.
- 85 Sahara K, Mino-Kenudson M, Brugge W, *et al.* Branch duct intraductal papillary mucinous neoplasms: does cyst size change the tip of the scale? A critical analysis of the revised international consensus guidelines in a large single-institutional series. *Ann Surg* 2013;258:466–75.
- 86 Fritz S, Klaus M, Bergmann F, *et al.* Pancreatic main-duct involvement in branch-duct IPMNs: an underestimated risk. *Ann Surg* 2014;260:848–55. discussion 55–6.
- 87 Aso T, Ohtsuka T, Matsunaga T, *et al.* "High-risk stigmata" of the 2012 international consensus guidelines correlate with the malignant grade of branch duct intraductal papillary mucinous neoplasms of the pancreas. *Pancreas* 2014;43:1239–43.
- 88 Nguyen AH, Toste PA, Farrell JJ, *et al.* Current recommendations for surveillance and surgery of intraductal papillary mucinous neoplasms may overlook some patients with cancer. *J Gastrointest Surg* 2015;19:258–65.
- 89 Roch AM, Ceppa EP, DeWitt JM, *et al.* International consensus guidelines parameters for the prediction of malignancy in intraductal papillary mucinous neoplasm are not properly weighted and are not cumulative. *HPB (Oxford)* 2014;16:929–35.
- 90 Goh BK, Thng CH, Tan DM, *et al.* Evaluation of the Sendai and 2012 International Consensus Guidelines based on cross-sectional imaging findings performed for the initial triage of mucinous cystic lesions of the pancreas: a single institution experience with 114 surgically treated patients. *Am J Surg* 2014;208:202–9.
- 91 Dortch JD, Stauffer JA, Asbun HJ. Pancreatic resection for side-branch intraductal papillary mucinous neoplasm (SB-IPMN): a contemporary single-institution experience. *J Gastrointest Surg* 2015;19:1603–9.
- 92 Robles EP, Maire F, Cros J, *et al.* Accuracy of 2012 International Consensus Guidelines for the prediction of malignancy of branch-duct intraductal papillary mucinous neoplasms of the pancreas. *United European Gastroenterol J* 2016;4:580–6.
- 93 Seo N, Byun JH, Kim JH, *et al.* Validation of the 2012 International Consensus Guidelines using computed tomography and magnetic resonance imaging: branch duct and main duct intraductal papillary mucinous neoplasms of the pancreas. *Ann Surg* 2016;263:557–64.
- 94 Hackert T, Fritz S, Klaus M, *et al.* Main-duct intraductal papillary mucinous neoplasm: high cancer risk in duct diameter of 5 to 9mm. *Ann Surg* 2015;262:875–80. discussion 80–1.
- 95 Abdeljawad K, Vemulapalli KC, Schmidt CM, *et al.* Prevalence of malignancy in patients with pure main duct intraductal papillary mucinous neoplasms. *Gastrointest Endosc* 2014;79:623–9.
- 96 Hirono S, Tani M, Kawai M, *et al.* The carcinoembryonic antigen level in pancreatic juice and mural nodule size are predictors of malignancy for branch duct type intraductal papillary mucinous neoplasms of the pancreas. *Ann Surg* 2012;255:517–22.
- 97 Kawada N, Uehara H, Nagata S, *et al.* Mural nodule of 10 mm or larger as predictor of malignancy for intraductal papillary mucinous neoplasm of the pancreas: pathological and radiological evaluations. *Pancreatol* 2016;16:441–8.
- 98 Kobayashi N, Sugimori K, Shimamura T, *et al.* Endoscopic ultrasonographic findings predict the risk of carcinoma in branch duct intraductal papillary mucinous neoplasms of the pancreas. *Pancreatol* 2012;12:141–5.
- 99 Shimizu Y, Yamaue H, Maguchi H, *et al.* Predictors of malignancy in intraductal papillary mucinous neoplasm of the pancreas: analysis of 310 pancreatic resection patients at multiple high-volume centers. *Pancreas* 2013;42:883–8.
- 100 Crippa S, Bassi C, Salvia R, *et al.* Low progression of intraductal papillary mucinous neoplasms with worrisome features and high-risk stigmata undergoing non-operative management: a mid-term follow-up analysis. *Gut* 2017;66:495–506.
- 101 Kang MJ, Jang JY, Kim SJ, *et al.* Cyst growth rate predicts malignancy in patients with branch duct intraductal papillary mucinous neoplasms. *Clin Gastroenterol Hepatol* 2011;9:87–93.
- 102 Kwong WT, Lawson RD, Hunt G, *et al.* Rapid growth rates of suspected pancreatic cyst branch duct intraductal papillary mucinous neoplasms predict malignancy. *Dig Dis Sci* 2015;60:2800–6.
- 103 Han Y, Lee H, Kang JS, *et al.* Progression of pancreatic branch duct intraductal papillary mucinous neoplasm associates with cyst size. *Gastroenterology* 2018;154:576–84.
- 104 Lafemina J, Katabi N, Klimstra D, *et al.* Malignant progression in IPMN: a cohort analysis of patients initially selected for resection or observation. *Ann Surg Oncol* 2013;20:440–7.
- 105 Roch AM, Ceppa EP, Al-Haddad MA, *et al.* The natural history of main duct-involved, mixed-type intraductal papillary mucinous neoplasm: parameters predictive of progression. *Ann Surg* 2014;260:680–8.
- 106 Roch AM, DeWitt JM, Al-Haddad MA, *et al.* Nonoperative management of main pancreatic duct-involved intraductal papillary mucinous neoplasm might be indicated in select patients. *J Am Coll Surg* 2014;219:122–9.
- 107 Del Chiaro M, Ateez B, Hansson MR, *et al.* Survival analysis and risk for progression of intraductal papillary mucinous neoplasia of the pancreas (IPMN) under surveillance: a single-institution experience. *Ann Surg Oncol* 2017;24:1120–6.
- 108 Masica DL, Dal Molin M, Wolfgang CL, *et al.* A novel approach for selecting combination clinical markers of pathology applied to a large retrospective cohort of surgically resected pancreatic cysts. *J Am Med Assoc* 2017;24:145–52.
- 109 Woo SM, Ryu JK, Lee SH, *et al.* Branch duct intraductal papillary mucinous neoplasms in a retrospective series of 190 patients. *Br J Surg* 2009;96:405–11.
- 110 Sadakari Y, Ienaga J, Kobayashi K, *et al.* Cyst size indicates malignant transformation in branch duct intraductal papillary mucinous neoplasm of the pancreas without mural nodules. *Pancreas* 2010;39:232–6.
- 111 Jang JY, Park T, Lee S, *et al.* Validation of international consensus guidelines for the resection of branch duct-type intraductal papillary mucinous neoplasms. *Br J Surg* 2014;101:686–92.
- 112 Ohtsuka T, Kono H, Nagayoshi Y, *et al.* An increase in the number of predictive factors augments the likelihood of malignancy in branch duct intraductal papillary mucinous neoplasm of the pancreas. *Surgery* 2012;151:76–83.
- 113 Crippa S, Pezzilli R, Bissolati M, *et al.* Active surveillance beyond 5 years is required for presumed branch-duct intraductal papillary mucinous neoplasms undergoing non-operative management. *Am J Gastroenterol* 2017;112:1153–61.
- 114 Lawrence SA, Attiye MA, Seier K, *et al.* Should patients with cystic lesions of the pancreas undergo long-term radiographic surveillance? Results of 3024 patients evaluated at a single institution. *Ann Surg* 2017;266:536–44.
- 115 Sahara K, Ferrone CR, Brugge WR, *et al.* Effects of comorbidities on outcomes of patients with intraductal papillary mucinous neoplasms. *Clin Gastroenterol Hepatol* 2015;13:1816–23.
- 116 Pugliese L, Keskin M, Maisonneuve P, *et al.* Increased incidence of extrapancreatic neoplasms in patients with IPMN: fact or fiction? A critical systematic review. *Pancreatol* 2015;15:209–16.
- 117 Larghi A, Panic N, Capurso G, *et al.* Prevalence and risk factors of extrapancreatic malignancies in a large cohort of patients with intraductal papillary mucinous neoplasm (IPMN) of the pancreas. *Ann Oncol* 2013;24:1907–11.
- 118 Marchegiani G, Malleo G, D'Haese JG, *et al.* Association between pancreatic intraductal papillary mucinous neoplasms and extrapancreatic malignancies. *Clin Gastroenterol Hepatol* 2015;13:1162–9.
- 119 Mimura T, Masuda A, Matsumoto I, *et al.* Predictors of malignant intraductal papillary mucinous neoplasm of the pancreas. *J Clin Gastroenterol* 2010;44:e224–e229.
- 120 Tian X, Gao H, Ma Y, *et al.* Surgical treatment and prognosis of 96 cases of intraductal papillary mucinous neoplasms of the pancreas: a retrospective cohort study. *Int J Surg* 2015;13:49–53.

- 121 Sahora K, Fernández-del Castillo C, Dong F, *et al.* Not all mixed-type intraductal papillary mucinous neoplasms behave like main-duct lesions: implications of minimal involvement of the main pancreatic duct. *Surgery* 2014;156:611–21.
- 122 Scholten L, van Huijgevoort NC, Bruno M, *et al.* Surgical management of main duct IPMN and mixed type IPMN: an international survey and case-vignette study among experts. *Pancreatology* 2017;17:S87.
- 123 Ito T, Doi R, Yoshizawa A, *et al.* The distribution of atypical epithelium in main-duct type intraductal papillary mucinous neoplasms of the pancreas. *J Hepatobiliary Pancreat Sci* 2011;18:241–9. discussion 6–9.
- 124 Watanabe Y, Nishihara K, Niina Y, *et al.* Validity of the management strategy for intraductal papillary mucinous neoplasm advocated by the international consensus guidelines 2012: a retrospective review. *Surg Today* 2016;46:1045–52.
- 125 He J, Cameron JL, Ahuja N, *et al.* Is it necessary to follow patients after resection of a benign pancreatic intraductal papillary mucinous neoplasm? *J Am Coll Surg* 2013;216:657–65. discussion 65–7.
- 126 Tamura K, Ohtsuka T, Ideno N, *et al.* Treatment strategy for main duct intraductal papillary mucinous neoplasms of the pancreas based on the assessment of recurrence in the remnant pancreas after resection: a retrospective review. *Ann Surg* 2014;259:360–8.
- 127 Ogawa H, Itoh S, Ikeda M, *et al.* Intraductal papillary mucinous neoplasm of the pancreas: assessment of the likelihood of invasiveness with multisection CT. *Radiology* 2008;248:876–86.
- 128 Shin SH, Han DJ, Park KT, *et al.* Validating a simple scoring system to predict malignancy and invasiveness of intraductal papillary mucinous neoplasms of the pancreas. *World J Surg* 2010;34:776–83.
- 129 Jun DY, Kwon HJ, Kim SG, *et al.* Predictive factors for invasive intraductal papillary mucinous neoplasm of the pancreas. *Korean J Hepatobiliary Pancreat Surg* 2011;15:237–42.
- 130 Kawakubo K, Tada M, Isayama H, *et al.* Disease-specific mortality among patients with intraductal papillary mucinous neoplasm of the pancreas. *Clin Gastroenterol Hepatol* 2014;12:486–91.
- 131 Kang MJ, Jang JY, Lee S, *et al.* Clinicopathological meaning of size of main-duct dilatation in intraductal papillary mucinous neoplasm of pancreas: proposal of a simplified morphological classification based on the investigation on the size of main pancreatic duct. *World J Surg* 2015;39:2006–13.
- 132 Fritz S, Hackert T, Hinz U, *et al.* Role of serum carbohydrate antigen 19-9 and carcinoembryonic antigen in distinguishing between benign and invasive intraductal papillary mucinous neoplasm of the pancreas. *Br J Surg* 2011;98:104–10.
- 133 Wong J, Weber J, Centeno BA, *et al.* High-grade dysplasia and adenocarcinoma are frequent in side-branch intraductal papillary mucinous neoplasm measuring less than 3 cm on endoscopic ultrasound. *J Gastrointest Surg* 2013;17:78–85. discussion p-5.
- 134 Jang JY, Kim SW, Lee SE, *et al.* Treatment guidelines for branch duct type intraductal papillary mucinous neoplasms of the pancreas: when can we operate or observe? *Ann Surg Oncol* 2008;15:199–205.
- 135 Fritz S, Klauss M, Bergmann F, *et al.* Small (Sendai negative) branch-duct IPMNs. *Ann Surg* 2012;256:313–20.
- 136 Goh BK. International guidelines for the management of pancreatic intraductal papillary mucinous neoplasms. *World J Gastroenterol* 2015;21:9833–7.
- 137 Sugiyama M, Izumisato Y, Abe N, *et al.* Predictive factors for malignancy in intraductal papillary-mucinous tumours of the pancreas. *Br J Surg* 2003;90:1244–9.
- 138 Del Chiaro M, Verbeke CS, Kartalis N, *et al.* Short-term results of a magnetic resonance imaging-based Swedish screening program for individuals at risk for pancreatic cancer. *JAMA Surg* 2015;150:512–8.
- 139 Faitot F, Gaujoux S, Barbier L, *et al.* Reappraisal of pancreatic enucleations: a single-center experience of 126 procedures. *Surgery* 2015;158:201–10.
- 140 Goudard Y, Gaujoux S, Dokmak S, *et al.* Reappraisal of central pancreatectomy a 12-year single-center experience. *JAMA Surg* 2014;149:356–63.
- 141 Partelli S, Fernandez-Del Castillo C, Bassi C, *et al.* Invasive intraductal papillary mucinous carcinomas of the pancreas: predictors of survival and the role of lymph node ratio. *Ann Surg* 2010;251:477–82.
- 142 Tol JA, Gouma DJ, Bassi C, *et al.* Definition of a standard lymphadenectomy in surgery for pancreatic ductal adenocarcinoma: a consensus statement by the International Study Group on Pancreatic Surgery (ISGPS). *Surgery* 2014;156:591–600.
- 143 Ohtsuka T, Kono H, Tanabe R, *et al.* Follow-up study after resection of intraductal papillary mucinous neoplasm of the pancreas; special references to the multifocal lesions and development of ductal carcinoma in the remnant pancreas. *Am J Surg* 2012;204:44–8.
- 144 Salvia R, Partelli S, Crippa S, *et al.* Intraductal papillary mucinous neoplasms of the pancreas with multifocal involvement of branch ducts. *Am J Surg* 2009;198:709–14.
- 145 Fritz S, Schirren M, Klaus M, *et al.* Clinicopathologic characteristics of patients with resected multifocal intraductal papillary mucinous neoplasm of the pancreas. *Surgery* 2012;152:S74–S80.
- 146 Rosenblatt R, Dorfman V, Epelboym I, *et al.* Demographic features and natural history of intermediate-risk multifocal versus unifocal intraductal papillary mucinous neoplasms. *Pancreas* 2015;44:478–83.
- 147 Matthaehi H, Norris AL, Tsiatis AC, *et al.* Clinicopathological characteristics and molecular analyses of multifocal intraductal papillary mucinous neoplasms of the pancreas. *Ann Surg* 2012;255:326–33.
- 148 Kwon JH, Kim SC, Song KB, *et al.* Surgical outcomes of multifocal branch duct intraductal papillary mucinous neoplasms of pancreas. *Korean J Hepatobiliary Pancreat Surg* 2014;18:152–8.
- 149 Yamaguchi J, Kaneoka Y, Maeda A, *et al.* Positive surgical margins in surgically treated unifocal and multifocal IPMN. *Int J Surg* 2016;28:51–5.
- 150 Fujii T, Kato K, Kadera Y, *et al.* Prognostic impact of pancreatic margin status in the intraductal papillary mucinous neoplasms of the pancreas. *Surgery* 2010;148:285–90.
- 151 Marchegiani G, Mino-Kenudson M, Ferrone CR, *et al.* Patterns of recurrence after resection of IPMN. *Ann Surg* 2015;262:1108–14.
- 152 Pea A, Yu J, Rezaee N, *et al.* Targeted DNA sequencing reveals patterns of local progression in the pancreatic remnant following resection of intraductal papillary mucinous neoplasm (IPMN) of the pancreas. *Ann Surg* 2017;266:133–141.
- 153 White R, D'Angelica M, Katabi N, *et al.* Fate of the remnant pancreas after resection of noninvasive intraductal papillary mucinous neoplasm. *J Am Coll Surg* 2007;204:987–93. discussion 93–5.
- 154 Park J, Lee KT, Jang TH, *et al.* Risk factors associated with the postoperative recurrence of intraductal papillary mucinous neoplasms of the pancreas. *Pancreas* 2011;40:46–51.
- 155 Nara S, Shimada K, Sakamoto Y, *et al.* Clinical significance of frozen section analysis during resection of intraductal papillary mucinous neoplasm: should a positive pancreatic margin for adenoma or borderline lesion be resected additionally? *J Am Coll Surg* 2009;209:614–21.
- 156 Landa J, Allen P, D'Angelica M, *et al.* Recurrence patterns of intraductal papillary mucinous neoplasms of the pancreas on enhanced computed tomography. *J Comput Assist Tomogr* 2009;33:838–43.
- 157 Leng KM, Wang ZD, Zhao JB, *et al.* Impact of pancreatic margin status and lymph node metastases on recurrence after resection for invasive and noninvasive intraductal papillary mucinous neoplasms of the pancreas: a meta-analysis. *Dig Surg* 2012;29:213–25.
- 158 Miller JR, Meyer JE, Waters JA, *et al.* Outcome of the pancreatic remnant following segmental pancreatectomy for non-invasive intraductal papillary mucinous neoplasm. *HPB (Oxford)* 2011;13:759–66.
- 159 Moriya T, Traverso W. Fate of the pancreatic remnant after resection for an intraductal papillary mucinous neoplasm: a longitudinal level II cohort study. *Arch Surg* 2012;147:528–34.
- 160 Bhardwaj N, Dennison AR, Maddern GJ, *et al.* Management implications of resection margin histology in patients undergoing resection for IPMN: a meta-analysis. *Pancreatology* 2016;16:309–17.
- 161 Kang MJ, Jang JY, Lee KB, *et al.* Long-term prospective cohort study of patients undergoing pancreatectomy for intraductal papillary mucinous neoplasm of the pancreas: implications for postoperative surveillance. *Ann Surg* 2014;260:356–63.
- 162 Frankel TL, LaFemina J, Bamboat ZM, *et al.* Dysplasia at the surgical margin is associated with recurrence after resection of non-invasive intraductal papillary mucinous neoplasms. *HPB (Oxford)* 2013;15:814–21.
- 163 Xourafas D, Tavakkoli A, Clancy TE, *et al.* Noninvasive intraductal papillary mucinous neoplasms and mucinous cystic neoplasms: recurrence rates and postoperative imaging follow-up. *Surgery* 2015;157:473–83.
- 164 Yogi T, Hijioka S, Imaoka H, *et al.* Risk factors for postoperative recurrence of intraductal papillary mucinous neoplasms of the pancreas based on a long-term follow-up study: proposals for follow-up strategies. *J Hepatobiliary Pancreat Sci* 2015;22:757–65.
- 165 Raut CP, Cleary KR, Staerckel GA, *et al.* Intraductal papillary mucinous neoplasms of the pancreas: effect of invasion and pancreatic margin status on recurrence and survival. *Ann Surg Oncol* 2006;13:582–94.
- 166 Eguchi H, Ishikawa O, Ohigashi H, *et al.* Role of intraoperative cytology combined with histology in detecting continuous and skip type intraductal cancer existence for intraductal papillary mucinous carcinoma of the pancreas. *Cancer* 2006;107:2567–75.
- 167 Farrell JJ, Fernández-del Castillo C. Pancreatic cystic neoplasms: management and unanswered questions. *Gastroenterology* 2013;144:1303–15.
- 168 Kaneko T, Nakao A, Nomoto S, *et al.* Intraoperative pancreatoscopy with the ultrathin pancreatoscope for mucin-producing tumors of the pancreas. *Arch Surg* 1998;133:263–7.
- 169 Pucci MJ, Johnson CM, Punja VP, *et al.* Intraoperative pancreatoscopy: a valuable tool for pancreatic surgeons? *J Gastrointest Surg* 2014;18:1100–7.
- 170 Yokoyama Y, Nagino M, Oda K, *et al.* Clinicopathologic features of re-resected cases of intraductal papillary mucinous neoplasms (IPMNs). *Surgery* 2007;142:136–42.
- 171 Cuillerier E, Cellier C, Palazzo L, *et al.* Outcome after surgical resection of intraductal papillary and mucinous tumors of the pancreas. *Am J Gastroenterol* 2000;95:441–5.
- 172 Salvia R, Fernández-del Castillo C, Bassi C, *et al.* Main-duct intraductal papillary mucinous neoplasms of the pancreas: clinical predictors of malignancy and long-term survival following resection. *Ann Surg* 2004;239:678–85. discussion 85–7.



- 173 Picicchi M, Crippa S, Del Chiaro M, *et al.* Outcomes of intraductal papillary mucinous neoplasm with "Sendai-positive" criteria for resection undergoing non-operative management. *Dig Liver Dis* 2013;45:584–8.
- 174 Ammori JB, Do RK, Brennan MF, *et al.* Uncinate duct dilation in intraductal papillary mucinous neoplasms of the pancreas: a radiographic finding with potentially increased malignant potential. *J Gastrointest Surg* 2014;18:911–6.
- 175 Marchegiani G, Mino-Kenudson M, Ferrone CR, *et al.* Oncocytic-type intraductal papillary mucinous neoplasms: a unique malignant pancreatic tumor with good long-term prognosis. *J Am Coll Surg* 2015;220:839–44.
- 176 Painsi M, Crippa S, Scopelliti F, *et al.* Extent of surgery and implications of transection margin status after resection of IPMNs. *Gastroenterol Res Pract* 2014;2014:1–10.
- 177 Ducreux M, Cuhna AS, Caramella C, *et al.* Cancer of the pancreas: ESMO Clinical Practice Guidelines for diagnosis, treatment and follow-up. *Ann Oncol* 2015;26(suppl 5):v56–v68.
- 178 Canto MI, Harinck F, Hruban RH, *et al.* International Cancer of the Pancreas Screening (CAPS) consortium summit on the management of patients with increased risk for familial pancreatic cancer. *Gut* 2013;62:339–47.
- 179 Konings IC, Harinck F, Poley JW, *et al.* Prevalence and progression of pancreatic cystic precursor lesions differ between groups at high risk of developing pancreatic cancer. *Pancreas* 2017;46:28–34.
- 180 Bartsch DK, Slater EP, Carrato A, *et al.* Refinement of screening for familial pancreatic cancer. *Gut* 2016;65:1314–21.
- 181 Vasen H, Ibrahim I, Ponce CG, *et al.* Benefit of surveillance for pancreatic cancer in high-risk individuals: outcome of long-term prospective follow-up studies from three European expert centers. *J Clin Oncol* 2016;34:2010–9.
- 182 Agarwal A, Scott FI, Ahmad NA, *et al.* Chronic immunosuppression does not potentiate the malignant progression of mucinous pancreatic cystic lesions. *Pancreatol* 2016;16:900–4.
- 183 Dorfman V, Verna EC, Poneris JM, *et al.* Progression of incidental intraductal papillary mucinous neoplasms of the pancreas in liver transplant recipients. *Pancreas* 2016;45:620–5.
- 184 Gill KR, Pelaez-Luna M, Keaveny A, *et al.* Branch duct intraductal papillary mucinous neoplasm of the pancreas in solid organ transplant recipients. *Am J Gastroenterol* 2009;104:1256–61.
- 185 Lennon AM, Victor D, Zaheer A, *et al.* Liver transplant patients have a risk of progression similar to that of sporadic patients with branch duct intraductal papillary mucinous neoplasms. *Liver Transpl* 2014;20:1462–7.
- 186 Vidhyakorn S, Siripongsakun S, Yu J, *et al.* Longterm follow-up of small pancreatic cystic lesions in liver transplant recipients. *Liver Transpl* 2017;23:324–9.
- 187 Oh HC, Brugge WR. EUS-guided pancreatic cyst ablation: a critical review (with video). *Gastrointest Endosc* 2013;77:526–33.
- 188 Oh HC, Seo DW, Song TJ, *et al.* Endoscopic ultrasonography-guided ethanol lavage with paclitaxel injection treats patients with pancreatic cysts. *Gastroenterology* 2011;140:172–9.
- 189 Gan SI, Thompson CC, Lauwers GY, *et al.* Ethanol lavage of pancreatic cystic lesions: initial pilot study. *Gastrointest Endosc* 2005;61:746–52.
- 190 Park JK, Song BJ, Ryu JK, *et al.* Clinical outcomes of endoscopic ultrasonography-guided pancreatic cyst ablation. *Pancreas* 2016;45:889–94.
- 191 Gómez V, Takahashi N, Levy MJ, *et al.* EUS-guided ethanol lavage does not reliably ablate pancreatic cystic neoplasms (with video). *Gastrointest Endosc* 2016;83:914–20.
- 192 Nilsson LN, Keane MG, Shamali A, *et al.* Nature and management of pancreatic mucinous cystic neoplasm (MCN): a systematic review of the literature. *Pancreatol* 2016;16:1028–36.
- 193 Naganuma S, Honda K, Noriki S, *et al.* Ruptured mucinous cystic neoplasm with an associated invasive carcinoma of pancreatic head in a pregnant woman: report of a case and review of literature. *Pathol Int* 2011;61:28–33.
- 194 Tanaka M, Fernández-del Castillo C, Adsay V, *et al.* International consensus guidelines 2012 for the management of IPMN and MCN of the pancreas. *Pancreatol* 2012;12:183–97.
- 195 Crippa S, Fernández-Del Castillo C, Salvia R, *et al.* Mucin-producing neoplasms of the pancreas: an analysis of distinguishing clinical and epidemiologic characteristics. *Clin Gastroenterol Hepatol* 2010;8:213–9.
- 196 Iacono C, Verlato G, Ruzzenente A, *et al.* Systematic review of central pancreatectomy and meta-analysis of central versus distal pancreatectomy. *Br J Surg* 2013;100:873–85.
- 197 Mehrabi A, Hafezi M, Arvin J, *et al.* A systematic review and meta-analysis of laparoscopic versus open distal pancreatectomy for benign and malignant lesions of the pancreas: it's time to randomize. *Surgery* 2015;157:45–55.
- 198 Jais B, Rebours V, Malleo G, *et al.* Serous cystic neoplasm of the pancreas: a multinational study of 2622 patients under the auspices of the International Association of Pancreatology and European Pancreatic Club (European Study Group on Cystic Tumors of the Pancreas). *Gut* 2016;65:305–12.
- 199 Reid MD, Choi HJ, Memis B, *et al.* Serous neoplasms of the pancreas: a clinicopathologic analysis of 193 cases and literature review with new insights on macrocystic and solid variants and critical reappraisal of so-called "serous cystadenocarcinoma". *Am J Surg Pathol* 2015;39:1597–610.
- 200 Strobel O, Z'graggen K, Schmitz-Winnenthal FH, *et al.* Risk of malignancy in serous cystic neoplasms of the pancreas. *Digestion* 2003;68:24–33.
- 201 Galanis C, Zamani A, Cameron JL, *et al.* Resected serous cystic neoplasms of the pancreas: a review of 158 patients with recommendations for treatment. *J Gastrointest Surg* 2007;11:820–6.
- 202 Khashab MA, Shin EJ, Amateau S, *et al.* Tumor size and location correlate with behavior of pancreatic serous cystic neoplasms. *Am J Gastroenterol* 2011;106:1521–6.
- 203 Pelaez-Luna MC, Moctezuma-Velázquez C, Hernández-Calleros J, *et al.* Serous cystadenomas follow a benign and asymptomatic course and do not present a significant size change during follow-up. *Rev Invest Clin* 2015;67:344–9.
- 204 Reid MD, Choi H, Balci S, *et al.* Serous cystic neoplasms of the pancreas: clinicopathologic and molecular characteristics. *Semin Diagn Pathol* 2014;31:475–83.
- 205 El-Hayek KM, Brown N, O'Rourke C, *et al.* Rate of growth of pancreatic serous cystadenoma as an indication for resection. *Surgery* 2013;154:794–802.
- 206 Malleo G, Bassi C, Rossini R, *et al.* Growth pattern of serous cystic neoplasms of the pancreas: observational study with long-term magnetic resonance surveillance and recommendations for treatment. *Gut* 2012;61:746–51.
- 207 Menard A, Tomlinson G, Cleary S, *et al.* Serous cystadenomas of the pancreas: long-term follow-up measurement of growth rate. *Can Assoc Radiol J* 2011;62:190–6.
- 208 Chalian H, Töre HG, Rezaei P, *et al.* MDCT evaluation of the growth kinetics of serous and benign mucinous cystic neoplasms of the pancreas. *Cancer Imaging* 2011;11:116–22.
- 209 Das A, Wells CD, Nguyen CC. Incidental cystic neoplasms of pancreas: what is the optimal interval of imaging surveillance? *Am J Gastroenterol* 2008;103:1657–62.
- 210 Tseng JF, Warshaw AL, Sahani DV, *et al.* Serous cystadenoma of the pancreas: tumor growth rates and recommendations for treatment. *Ann Surg* 2005;242:413–9.
- 211 Bassi C, Salvia R, Molinari E, *et al.* Management of 100 consecutive cases of pancreatic serous cystadenoma: wait for symptoms and see at imaging or vice versa? *World J Surg* 2003;27:319–23.
- 212 Morris-Stiff G, Falk GA, Chalikhonda S, *et al.* Natural history of asymptomatic pancreatic cystic neoplasms. *HPB (Oxford)* 2013;15:175–81.
- 213 Kim MJ, Choi DW, Choi SH, *et al.* Surgical treatment of solid pseudopapillary neoplasms of the pancreas and risk factors for malignancy. *Br J Surg* 2014;101:1266–71.
- 214 Cai Y, Ran X, Xie S, *et al.* Surgical management and long-term follow-up of solid pseudopapillary tumor of pancreas: a large series from a single institution. *J Gastrointest Surg* 2014;18:935–40.
- 215 Wang WB, Zhang TP, Sun MQ, *et al.* Solid pseudopapillary tumor of the pancreas with liver metastasis: clinical features and management. *Eur J Surg Oncol* 2014;40:1572–7.
- 216 Cheng K, Shen B, Peng C, *et al.* Synchronous portal-superior mesenteric vein or adjacent organ resection for solid pseudopapillary neoplasms of the pancreas: a single-institution experience. *Am Surg* 2013;79:534–9.
- 217 Lee HS, Kim HK, Shin BK, *et al.* A rare case of recurrent metastatic solid pseudopapillary neoplasm of the pancreas. *J Pathol Transl Med* 2017;51:87–91.
- 218 Kawamoto S, Johnson PT, Shi C, *et al.* Pancreatic neuroendocrine tumor with cystlike changes: evaluation with MDCT. *AJR Am J Roentgenol* 2013;200:W283–90.
- 219 Park HS, Kim SY, Hong SM, *et al.* Hypervascular solid-appearing serous cystic neoplasms of the pancreas: differential diagnosis with neuroendocrine tumours. *Eur Radiol* 2016;26:1348–58.
- 220 Jang KM, Kim SH, Song KD, *et al.* Differentiation of solid-type serous cystic neoplasm from neuroendocrine tumour in the pancreas: value of abdominal MRI with diffusion-weighted imaging in comparison with MDCT. *Clin Radiol* 2015;70:153–60.
- 221 Koh YX, Chok AY, Zheng HL, *et al.* A systematic review and meta-analysis of the clinicopathologic characteristics of cystic versus solid pancreatic neuroendocrine neoplasms. *Surgery* 2014;156:83–96.
- 222 Partelli S, Cirocchi R, Crippa S, *et al.* Systematic review of active surveillance versus surgical management of asymptomatic small non-functioning pancreatic neuroendocrine neoplasms. *Br J Surg* 2017;104:34–41.
- 223 Akbulut S, Yavuz R, Sogutcu N, *et al.* Hydatid cyst of the pancreas: report of an undiagnosed case of pancreatic hydatid cyst and brief literature review. *World J Gastrointest Surg* 2014;6:190–202.
- 224 Mondal U, Henkes N, Henkes D, Rosenkranz L. Cavernous hemangioma of adult pancreas: a case report and literature review. *World J Gastroenterol* 2015;21:9793–802.
- 225 Matsubayashi H, Aikawa Y, Sugiyama T, *et al.* Pancreatic lymphoepithelial cyst showing multiple floating ball-like appearances. *J Gastrointest Liver Dis* 2016;25:239–42.
- 226 Wolf AM, Shirley LA, Winter JM, *et al.* Acinar cell cystadenoma of the pancreas: report of three cases and literature review. *J Gastrointest Surg* 2013;17:1322–6.
- 227 Albayrak A, Yildirim U, Aydin M. Dermoid cyst of the pancreas: a report of an unusual case and a review of the literature. *Case Rep Pathol* 2013;2013:1–5.
- 228 Dong F, Zheng Y, Wu JJ, *et al.* Hemolymphangioma: a rare differential diagnosis of cystic-solid or cystic tumors of the pancreas. *World J Gastroenterol* 2013;19:3520–3.
- 229 Kim YS, Cho JH. Rare nonneoplastic cysts of pancreas. *Clin Endosc* 2015;48:31–8.

- 230 Otsuka T, Morizane C, Nara S, *et al.* Gemcitabine in patients with intraductal papillary mucinous neoplasm with an associated invasive carcinoma of the pancreas. *Pancreas* 2013;42:889–92.
- 231 Alexander BM, Fernandez-Del Castillo C, Ryan DP, *et al.* Intraductal papillary mucinous adenocarcinoma of the pancreas: clinical outcomes, prognostic factors, and the role of adjuvant therapy. *Gastrointest Cancer Res* 2011;4:116–21.
- 232 Worni M, Akushevich I, Gloor B, *et al.* Adjuvant radiotherapy in the treatment of invasive intraductal papillary mucinous neoplasm of the pancreas: an analysis of the surveillance, epidemiology, and end results registry. *Ann Surg Oncol* 2012;19:1316–23.
- 233 Turrini O, Waters JA, Schnellendorfer T, *et al.* Invasive intraductal papillary mucinous neoplasm: predictors of survival and role of adjuvant therapy. *HPB* 2010;12:447–55.
- 234 Wasif N, Bentrem DJ, Farrell JJ, *et al.* Invasive intraductal papillary mucinous neoplasm versus sporadic pancreatic adenocarcinoma: a stage-matched comparison of outcomes. *Cancer* 2010;116:3369–77.
- 235 Swartz MJ, Hsu CC, Pawlik TM, *et al.* Adjuvant chemoradiotherapy after pancreatic resection for invasive carcinoma associated with intraductal papillary mucinous neoplasm of the pancreas. *Int J Radiat Oncol Biol Phys* 2010;76:839–44.
- 236 Le H, Ziogas A, Rhee JM, *et al.* A population-based, descriptive analysis of malignant intraductal papillary mucinous neoplasms of the pancreas. *Cancer Epidemiol Biomarkers Prev* 2008;17:2737–41.
- 237 Caponi S, Vasile E, Funel N, *et al.* Adjuvant chemotherapy seems beneficial for invasive intraductal papillary mucinous neoplasms. *Eur J Surg Oncol* 2013;39:396–403.
- 238 McMillan MT, Lewis RS, Drebin JA, *et al.* The efficacy of adjuvant therapy for pancreatic invasive intraductal papillary mucinous neoplasm (IPMN). *Cancer* 2016;122:521–33.
- 239 Fong ZV, Castillo CF. Intraductal papillary mucinous adenocarcinoma of the pancreas: clinical outcomes, prognostic factors, and the role of adjuvant therapy. *Viszeralmedizin* 2015;131:43–6.
- 240 Hirono S, Tani M, Kawai M, *et al.* Treatment strategy for intraductal papillary mucinous neoplasm of the pancreas based on malignant predictive factors. *Arch Surg* 2009;144:345–9. discussion 9–50.
- 241 Yachha SK, Chetri K, Saraswat VA, *et al.* Management of childhood pancreatic disorders: a multidisciplinary approach. *J Pediatr Gastroenterol Nutr* 2003;36:206–12.
- 242 Maire F, Hammel P, Terris B, *et al.* Prognosis of malignant intraductal papillary mucinous tumours of the pancreas after surgical resection. Comparison with pancreatic ductal adenocarcinoma. *Gut* 2002;51:717–22.
- 243 Le Borgne J, de Calan L, Partensky C. Cystadenomas and cystadenocarcinomas of the pancreas: a multiinstitutional retrospective study of 398 cases. French Surgical Association. *Ann Surg* 1999;230:152–61.
- 244 Westermarck S, Rangelova E, Ansorge C, *et al.* Cattell-Braasch maneuver combined with local hypothermia during superior mesenteric artery resection in pancreatotomy. *Langenbecks Arch Surg* 2016;401:1241–7.
- 245 Di Marco M, Vecchiarelli S, Macchini M, *et al.* Preoperative gemcitabine and oxaliplatin in a patient with ovarian metastasis from pancreatic cystadenocarcinoma. *Case Rep Gastroenterol* 2012;6:530–7.
- 246 Sacco Casamassima MG, Gause CD, Goldstein SD, *et al.* Pancreatic surgery for tumors in children and adolescents. *Pediatr Surg Int* 2016;32:779–88.
- 247 Prasad TV, Madhusudhan KS, Srivastava DN, *et al.* Transarterial chemoembolization for liver metastases from solid pseudopapillary epithelial neoplasm of pancreas: a case report. *World J Radiol* 2015;7:61–5.
- 248 Hofmann H, von Haken R, Werner J, *et al.* Unresectable isolated hepatic metastases from solid pseudopapillary neoplasm of the pancreas: a case report of chemosaturation with high-dose melphalan. *Pancreatol* 2014;14:546–9.
- 249 Honore C, Goere D, Dartigues P, *et al.* Peritoneal carcinomatosis from solid pseudopapillary neoplasm (Frantz's tumour) of the pancreas treated with HIPEC. *Anticancer Res* 2012;32:1069–73.
- 250 Ansari D, Elebro J, Tingstedt B, *et al.* Single-institution experience with solid pseudopapillary neoplasm of the pancreas. *Scand J Gastroenterol* 2011;46:1492–7.
- 251 Maffuz A, Bustamante FT, Silva JA, *et al.* Preoperative gemcitabine for unresectable, solid pseudopapillary tumour of the pancreas. *Lancet Oncol* 2005;6:185–6.
- 252 Matsuda Y, Imai Y, Kawata S, *et al.* Papillary-cystic neoplasm of the pancreas with multiple hepatic metastases: a case report. *Gastroenterol Jpn* 1987;22:379–84.
- 253 Valente R, Capurso G, Pierantognetti P, *et al.* Simultaneous intraductal papillary neoplasms of the bile duct and pancreas treated with chemoradiotherapy. *World J Gastrointest Oncol* 2012;4:22–5.
- 254 Irtan S, Galmiche-Rolland L, Elie C, *et al.* Recurrence of solid pseudopapillary neoplasms of the pancreas: results of a nationwide study of risk factors and treatment modalities. *Pediatr Blood Cancer* 2016;63:1515–21.
- 255 Esposito I, Kleeff J, Bergmann F, *et al.* Most pancreatic cancer resections are R1 resections. *Ann Surg Oncol* 2008;15:1651–60.
- 256 Verbeke CS, Gladhaug IP. Dissection of pancreatic resection specimens. *Surg Pathol Clin* 2016;9:523–38.
- 257 Adsay V, Mino-Kenudson M, Furukawa T, *et al.* Pathologic evaluation and reporting of intraductal papillary mucinous neoplasms of the pancreas and other tumoral intraepithelial neoplasms of pancreatobiliary tract. *Ann Surg* 2016;263:162–77.
- 258 Basturk O, Hong SM, Wood LD, *et al.* A revised classification system and recommendations from the Baltimore consensus meeting for neoplastic precursor lesions in the pancreas. *Am J Surg Pathol* 2015;39:1730–41.
- 259 Furukawa T, Klöppel G, Volkan Adsay N, *et al.* Classification of types of intraductal papillary-mucinous neoplasm of the pancreas: a consensus study. *Virchows Arch* 2005;447:794–9.
- 260 Furukawa T, Hatori T, Fujita I, *et al.* Prognostic relevance of morphological types of intraductal papillary mucinous neoplasms of the pancreas. *Gut* 2011;60:509–16.
- 261 Brierley JD, Gospodarowicz MK, Wittenkind CH, eds. *TNM classification of malignant tumours*. 8th edn: Wiley-Blackwell, 2017:272.
- 262 Distler M, Kersting S, Niedergethmann M, *et al.* Pathohistological subtype predicts survival in patients with intraductal papillary mucinous neoplasm (IPMN) of the pancreas. *Ann Surg* 2013;258:324–30.
- 263 Scourtas A, Dudley JC, Brugge WR, *et al.* Preoperative characteristics and cytological features of 136 histologically confirmed pancreatic mucinous cystic neoplasms. *Cancer Cytopathol* 2017;125:169–77.
- 264 Pitman MB, Yaeger KA, Brugge WR, *et al.* Prospective analysis of atypical epithelial cells as a high-risk cytologic feature for malignancy in pancreatic cysts. *Cancer Cytopathol* 2013;121:29–36.
- 265 Pitman MB, Centeno BA, Ali SZ, *et al.* Standardized terminology and nomenclature for pancreatobiliary cytology: the Papanicolaou Society of Cytopathology guidelines. *Diagn Cytopathol* 2014;42:338–50.