

Extent of Liver Resection for Hilar Cholangiocarcinoma (Klatskin Tumor): How Much Is Enough?

Thomas M. van Gulik^a Anthony T. Ruys^a Oliver R.C. Busch^a Erik A.J. Rauws^b
Dirk J. Gouma^a

Departments of ^aSurgery and ^bGastroenterology, Academic Medical Center, Amsterdam, The Netherlands

Key Words

Hilar cholangiocarcinoma · Liver parenchyma · Liver function · Hemihepatectomy

Abstract

Background: Hilar resection in combination with extended liver resections has resulted in a higher rate of R0 resections and increased survival in patients with hilar cholangiocarcinoma (HCCA). This aggressive surgical approach is, however, associated with high rates of operative morbidity and mortality, largely due to postresectional liver failure. We previously reported a series after resection of HCCA in which R0 resection rate was 59% with a mortality rate of 10%. In this study, we assessed mortality of extended liver resections after optimizing liver functional reserve and application of parenchyma-sparing techniques. **Methods:** From 2008 until June 2010, 41 consecutive patients underwent resection on the suspicion of HCCA. Preoperative workup included staging laparoscopy, preoperative biliary drainage, assessment of volume/function of future remnant liver and radiation therapy to prevent seeding metastases. Modified right and left extended hemihepatectomies were performed preserving parts of segments 4 and 8, respectively, while pursuing complete excision of the tumor. Outcomes of resection were evaluated. **Results:** The majority of resections (78%) were performed for Bismuth type III–IV tumors. Preoperative biliary

drainage was undertaken in 37 (90%) patients. Hilar resection in combination with liver resection was performed in 35 (85%) patients. Of these resections, 61% were modified extended resections including central liver resections. The R0 resection rate was 92%. Postoperative morbidity and mortality rates were 54 and 7%, respectively. **Conclusion:** Strategies to optimize liver function and to reduce removal of functional liver parenchyma were associated with a decrease in mortality (7%) while undertaking extended resection for HCCA with an R0 resection rate of 92%.

Copyright © 2011 S. Karger AG, Basel

Introduction

Surgical treatment of hilar cholangiocarcinoma (HCCA) has shifted from local excision of the bile duct confluence at the liver hilum during the 1980s, to more extensive resections combined with major liver resection in the 1990s. This more aggressive surgical approach has resulted in a higher rate of R0 resections and, consequently, increased survival. Several centers specialized in hepato-pancreato-biliary surgery have recently reported improved survival with this surgical strategy; 5-year survival results range from 20 to 35% after extensive resections [1–3]. However, these results have been burdened by high rates of operative morbidity and mortality due to

this aggressive surgery. Most series report a hospital mortality of 5–10%, largely caused by postresectional liver failure [1, 2, 4, 5]. The way to decrease mortality of extended liver resections, therefore, is to increase liver functional reserve before resection and to apply parenchyma-sparing techniques with the extended liver resections that are necessary to radically remove the tumor. In this paper, we describe the strategies we have recently adopted to preoperatively optimize liver function and to reduce removal of functional liver parenchyma while undertaking extended resection for these hilar tumors.

Methods

Study Population

From 2008 until June 2010, 41 consecutive patients underwent resection on the suspicion of HCCA. Proximal tumor infiltration into the biliary tract was categorized according to the Bismuth-Corlette classification [6]. Outcomes were evaluated by assessment of R0 resection rate, postoperative morbidity and mortality [7].

Criteria for Resectability

The proximal extent of tumor into the intrahepatic biliary tree largely determines local resectability of HCCA. Whereas Bismuth type III tumors showing extension into the first segmental biliary ducts on one side of the liver are resectable using (extended) hemihepatectomy, Bismuth type IV tumors which extend into the first segmental ducts on both sides of the liver, are resectable only in selected cases. The anatomy of the biliary ducts at the hepatic duct confluence ultimately determines whether tumor-free ductal margins can be obtained with preservation of sufficient remnant liver in Bismuth type IV tumors [8]. The liver hilum features great variation in the anatomy of the biliary ducts. The hepatic duct confluence consists in 16% of cases of the right anterior (B5/8) and right posterior (B6/7) sectorial ducts draining together with the left hepatic duct into the common hepatic duct, forming a trifurcation [9]. Invasion of the left segmental ducts in combination with the right sectorial ducts at the liver hilum, although by definition a Bismuth type IV tumor, does not preclude a potentially curative resection. It is therefore important that each patient with a hilar tumor is assessed by an experienced team including hepatobiliary surgeons.

In addition, factors that determine whether a patient can undergo tumor resection are: involvement of main portal vein and/or hepatic artery, volume and function of future remnant liver, possibility of portal vein embolization (PVE) and adequate biliary drainage of future remnant liver segments. Metastasized disease is generally considered a contraindication for resection with the exception of lymph node metastases confined to the hepatoduodenal ligament.

Assessment of Volume and Function of Future Remnant Liver

CT volumetry is used to assess the volume of the remnant liver relative to total liver volume. In patients with HCCA, the safe volume of the remnant liver is preferably 40% after complete bili-

ary drainage. However, calculation of volume based on CT only provides indirect information on the functional capacity of the liver remnant. We therefore use ^{99m}Tc -mebrofenin scintigraphy in conjunction with CT volumetry to determine function of the future remnant liver, which has the additional advantage of providing information on segmental functional liver tissue [10]. Preoperative measurement of ^{99m}Tc -mebrofenin uptake proved more valuable than volume of the future remnant liver in postresectional risk assessment of liver failure and liver failure-related mortality. When future remnant liver volume or function is deemed insufficient, preoperative PVE is considered.

Preoperative Biliary Drainage

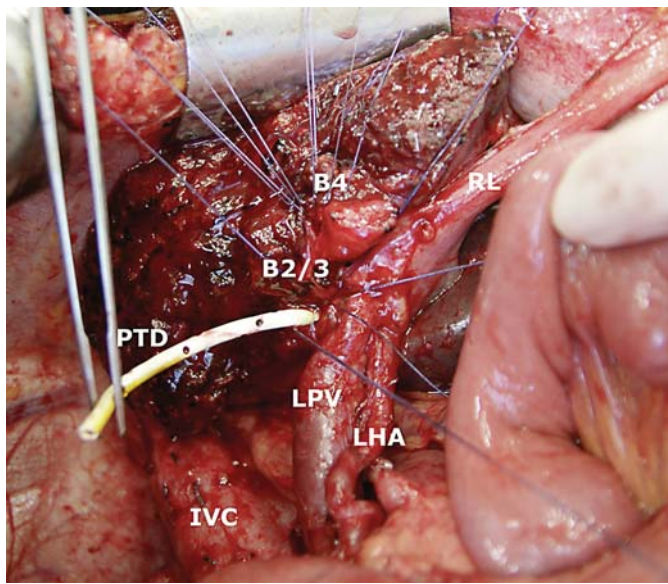
Patients with HCCA typically present with jaundice [11]. Obstructive jaundice affects liver functional reserve and reduces the regenerative capacity of the liver after resection. Jaundice for these reasons, is considered a significant risk factor in patients with HCCA requiring major liver resection. For optimal postoperative function and regeneration of the liver remnant, preoperative drainage of the biliary system is advised.

In our experience, percutaneous transhepatic biliary drainage outperformed endoscopic biliary drainage in patients with potentially resectable HCCA, showing fewer infectious complications and less drainage procedures [12]. An additional advantage of the percutaneous route of biliary drainage is that the biliary tubes are an aid to locate the bile ducts proximal of the tumor in the liver parenchyma and that after the resection has taken place, the tubes can be used as transanastomotic drains to facilitate healing of the hepaticojejunostomies. The tubes are removed after control cholangiography via the tubes 3–6 weeks later.

Extent of Resection

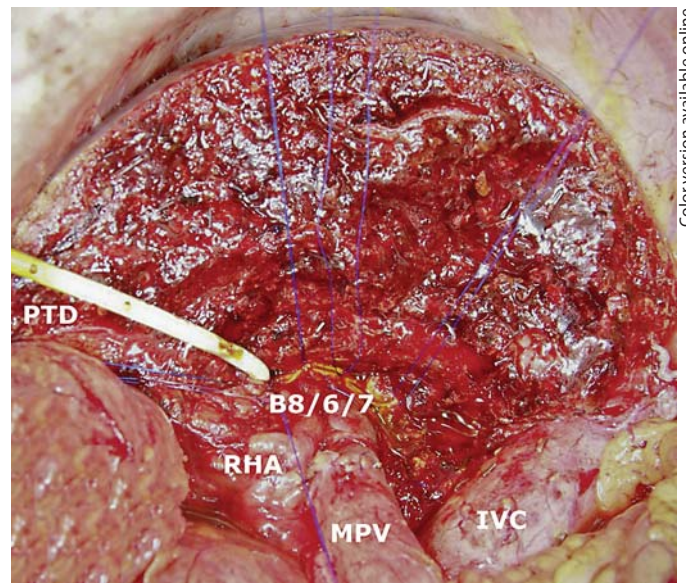
A more extensive surgical approach, as proposed by Japanese surgeons in the 1990s, has been applied in our center combining hilar resection with large liver resections for the majority of HCCA [8]. According to this strategy, radical resection of HCCA encompasses excision of the liver hilum en bloc with (extended) hemihepatectomy including the caudate lobe, excision of the portal vein bifurcation when involved and complete lymphadenectomy of the hepatoduodenal ligament [13]. This concept is based on a three-dimensional perception of the tumor located centrally in the liver. Tumor extension occurs from the bile duct confluence to the right and left along the main hepatic and segmental bile ducts, but also anteriorly into segment 4 and posteriorly into the bile ducts draining segment 1. It is therefore crucial that the central part of the liver along the anteroposterior axis through segment 1 and segment 4 is removed with liver resection, whether this would be a left-sided or right-sided resection. A right-sided resection therefore entails an extended right hemihepatectomy including segments 4 and 1, and leaving only segments 2 and 3 as liver remnant. These are large resections in which a significant volume of liver parenchyma is sacrificed leaving only the left lateral segment (s2/3) which usually constitutes 20–30% of total liver volume.

There is an advantage of a left-sided approach to resection since segment 4 is an anatomical part of the left liver, hence preserving the whole right liver. For these reasons, we prefer a left-sided approach to Bismuth type IV tumors provided the right hepatic artery is free, because coming from the left, there is a leeway to extend the resection including segment 5 and (part of) segment



Color version available online

Fig. 1. Resection surface after modified extended right hemihepatectomy including segment 1, in which the cranial part of segment 4 (4a) was preserved. The segmental duct openings of B2/3 and B4 are shown. The PTD cannula passing through B2/3 is cut for positioning through the hepaticojejunostomy. LPV = Left portal vein; LHA = left hepatic artery; IVC = inferior vena cava; RL = round ligament.



Color version available online

Fig. 2. Resection surface after modified extended left hepatectomy including segment 1, in which on the right side, segment 5 was resected while preserving part of segment 8. The segmental bile ducts were cut on the level of B8, B6 and B7. PTD = PTD cannula; MPV = main portal vein; RHA = right hepatic artery; IVC = inferior vena cava.

8, while preserving a higher volume of parenchyma than only segments 2 and 3.

Care is taken to control bile spill during resection in order to decrease the risk of postoperative seeding metastases. Firstly, after the common bile duct (CBD) is cut on the edge of the pancreas early during the operation, the stump of the CBD is meticulously closed to avoid bile spill. Secondly, the proximal, segmental bile ducts are cut in the liver remnant, preferably as the final step in the procedure, after the parenchymal transection has been completely executed and any additional procedures such as portal vein reconstruction have been finished. Hence, the tumor is removed with the specimen as soon as the proximal bile ducts have been cut minimizing exposure of the operative field to bile coming out of the affected bile ducts. The biliary-enteric anastomosis is subsequently carried out by end-to-side anastomoses of the segmental ducts to a Roux-en-Y jejunal loop.

Parenchyma-Preserving Techniques of Extended Liver Resection

The aim of parenchyma-preserving techniques is to compromise between the extent of resection and the sparing of functional liver tissue. While performing extended right hemihepatectomy (segments 1, 4, 5, 6, 7, 8), the cranial part of segment 4 (4a) may be preserved depending on the level in which the bile duct of segment 4 (B4) drains into the left hepatic duct relative to the tumor. When B4 joins the left hepatic duct just proximal to the confluence of right and left hepatic ducts, it is possible to resect this junction with the tumor while preserving the proximal part of B4 and the associated parenchyma of segment 4 (fig. 1). A separate biliary

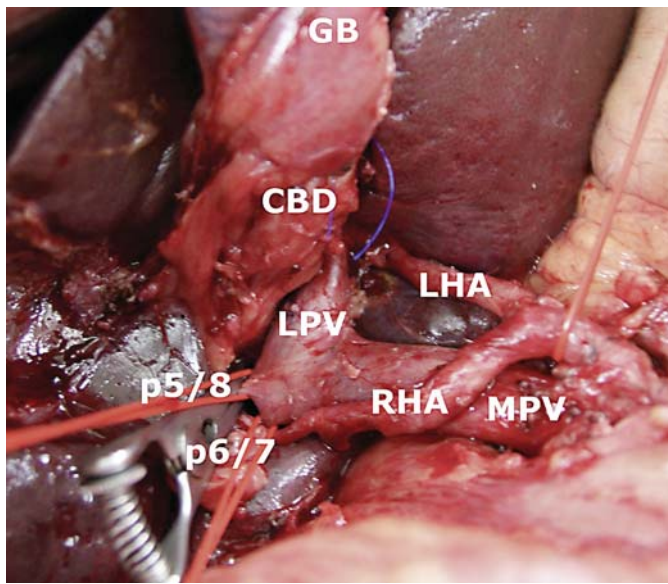
anastomosis with the subsegmental duct of 4 (B4a) is required in these cases, in addition to the anastomoses with B2/3. Likewise, in tumors predominantly arising from the left part of the biliary system (Bismuth type IIIb and IV), a modified extended left hepatectomy can be performed by resecting segments 1, 2, 3, 4, 5 and part of segment 8, preserving B8 and associated parenchyma on the cranial side (fig. 2).

As an alternative to extended right hemihepatectomy for predominantly right-sided tumors (Bismuth type IIIa and IV), when tumor infiltration into the ducts of segments 6 and 7 is limited and the right hepatic artery is not involved, a central liver resection (mesohepatectomy) can be performed while preserving the greater parts of segments 6 and 7, and the left lateral segments 2 and 3 (fig. 3, 4). These parenchyma-sparing resections can be devised only after precise assessment of biliary anatomy at the liver hilum. The modifications of extended resections undertaken in this series are summarized in table 1.

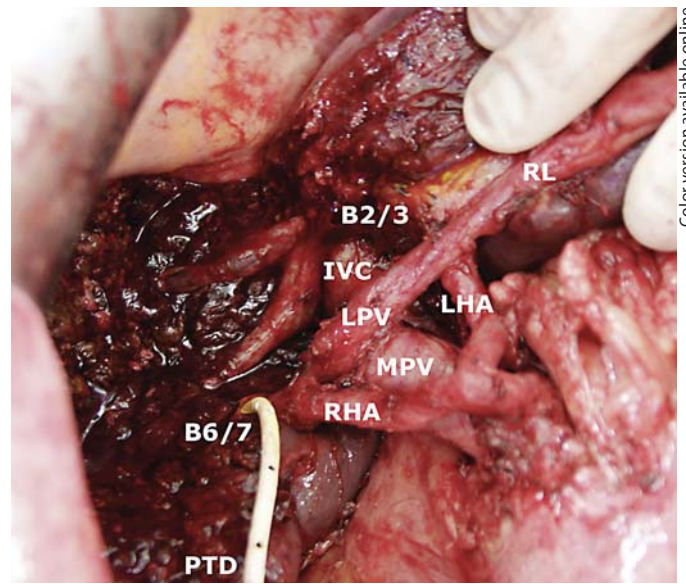
Results

Outcomes of Resection

The majority of resections (78%) were performed for Bismuth type III–IV tumors (table 2). Preoperative biliary drainage was undertaken in 37 (90%) patients, either endoscopically (ERCP) or using percutaneous transhepatic biliary drainage. Nine patients were treated with



Color version available online



Color version available online

Fig. 3. In preparation of central liver resection, the left portal vein (LPV) and left hepatic artery (LHA) are fully exposed, while the right anterior branch of the right portal vein (sling around p5/8) is isolated and divided. The anterior branch of the right hepatic artery (RHA) is also ligated and cut. The hepatic arterial and portal branches to segments 6 and 7 (sling around p6/7) are preserved. MPV = Main portal vein; CBD = cut end of distal CBD; GB = gallbladder.

Fig. 4. Central liver resection (mesohepatectomy) in which on the right side segments 6 and 7, and on the left side the lateral segments 2 and 3 are preserved. The openings of B2 and B3 (B2/3), and B6 and B7 (B6/7) are exposed. The PTD cannula (PTD) passes through B6/7. MPV = main portal vein; LPV = left portal vein; LHA = left hepatic artery; RHA = right hepatic artery; IVC = inferior vena cava; RL = round ligament.

both ERCP and percutaneous transhepatic cholangiodrainage (PTCD) to ultimately achieve adequate drainage of, at least, the liver segments to be preserved (future liver remnant). Half of the patients (51%) presented with hypertrophy of the future liver remnant due to portal tumor infiltration or longstanding cholestasis within the main tumor-bearing lobe of the liver.

Local resection was performed in 6 patients with Bismuth type I/II tumors (table 2). In the remaining 35 patients, hilar resection was combined with liver resection (85%). Of these resections, 61% were modified extended resections including central liver resections. In 18 patients, an extended right hemihepatectomy was performed; in 10 (56%) of them, the procedure was reduced leaving part of segment 4 (4a). In patients with Bismuth type IIIb tumors, most tumors (85%) were resected with left hemihepatectomy extended in the hilar area into segments 5 and 8 to include the parenchyma surrounding the sectorial ducts of the right biliary system. The greater part of segment 8 was preserved on the cranial side of the liver. In 4 patients, a central liver resection was performed preserving segments 6 and 7 of the right hemiliver, and segments 2 and 3 on the left side. Segment 1 was removed

en bloc in 32 of the resections (78%), and resection of the portal vein bifurcation was necessary in 9 (22%) patients in conjunction with extended hemihepatectomies (table 1).

Three tumors (7%) proved to be of benign origin on histopathological examination of the specimen, and were not taken into account when analyzing the microscopical margins of the resection. In patients with confirmed cholangiocarcinoma, the R0 resection rate was 92%. Postoperative morbidity rate was 54% (table 1). In the 3 patients who died in the postoperative period (hospital mortality 7%; table 1), liver failure was initiated by local complications (portal vein thrombosis, loss of segmental hepatic artery, pancreatic necrosis) rather than insufficient remnant liver volume per se.

Discussion

Excision with adequate resection margins offers the only potential for cure in patients with HCCA. Hilar resection in combination with extensive liver resections has shown to increase the R0 resection rate. Morbidity and

Table 1. Type of resection and postoperative results

Type of resection	
Local resection	6 (15)
Extended right hemihepatectomy	8 (20)
Modified right hemihepatectomy	10 (24)
Left hemihepatectomy	2 (5)
Modified extended left hemihepatectomy	11 (29)
Central liver resection	4 (10)
Segment 1 resection	
Yes	32 (78)
No	9 (22)
Portal vein reconstruction	
Yes	9 (22)
No	32 (78)
Radicality	
R0	35 (92) ¹
R1	3 (8) ¹
Benign	3 (7)
Morbidity (Clavien-Dindo classification)	
None	19 (46)
1+2	10 (24)
3	5 (12)
4	4 (10)
5 (mortality)	3 (7)

Figures indicate number of patients (%).

¹ Only malignant lesions were analyzed.

mortality, however, are high after extensive resections in patients with HCCA mainly because of poor functional reserve of the liver remnant. The challenge for the near future is to improve overall survival by, in the first place, decreasing mortality of the extended liver resections that are necessary to eradicate the tumor.

Preoperative optimization of function of the future remnant liver is crucial for the success of extended liver resections for HCCA. Although still controversial, most surgeons believe in a benefit of preoperative biliary drainage in patients with HCCA planned for hilar resection in conjunction with a large liver resection. Function and regenerative capacity of the liver parenchyma are greatly suppressed in patients with a central obstruction of the biliary tree, and fall short when the volume of residual liver is reduced. Biliary drainage enhances the quality of the liver parenchyma, and we therefore pursue preoperative biliary drainage of, at least, the future liver remnant in jaundiced patients with potentially resectable HCCA. Additional advantages of preoperative biliary drainage in the setting of HCCA are the treatment of segmental cholangitis and the definition of proximal extent of the tumor [14]. This policy differs in patients with a distal bile duct

Table 2. Preoperative characteristics

Bismuth	
I+II	9 (22)
IIIa	16 (39)
IIIb	10 (24)
IV	6 (15)
Preoperative biliary drainage	
None	4 (10)
ERCP	20 (49)
PTBD	8 (20)
Both	9 (22)
PVE	
Yes	2 (5)
No	39 (95)
Hypertrophy future remnant liver	
No	18 (44)
After PVE	2 (5)
Yes	21 (51)

Figures indicate number of patients (%).

obstruction requiring only resection of the pancreatic head, as postoperative recovery does not depend on regeneration of a reduced liver [15].

Preoperative CT volumetry is the standard method for calculation of the fraction of residual liver mass after a planned resection. Whereas in patients with normal liver parenchyma a future liver remnant >25–30% is considered sufficient to provide adequate metabolic function, a larger future liver remnant (>40%) is preferred in patients with HCCA because of compromised parenchymal function even in patients with a recently decompressed biliary system. Due to longstanding cholestasis or occlusion of the ipsilateral portal vein, a proportion of patients with HCCA present with atrophy of the main tumor-bearing lobe and a compensatory hypertrophy of the contralateral liver segments. This phenomenon occurred in 51% of patients in the present series and facilitated resection in terms of increased residual volume of the liver remnant.

In patients in whom CT volumetry shows too small future liver remnant (<40%), usually when an extended right hemihepatectomy is planned, preoperative PVE may be considered [16]. In our experience, however, PVE should be applied with caution in patients requiring extensive liver resection for HCCA. Firstly, PVE predetermines the side of the liver to be resected, i.e. the embolized, atrophic liver lobe. When during exploration the type of resection is reconsidered on the basis of intraoperative findings, the surgical approach cannot be switched to remove the nonembolized, hypertrophic lobe. Second-

ly, when the patient is found to be unresectable, the persisting embolized, atrophic liver segments are liable to septic complications since the affected bile ducts are often infected and incompletely drained [17]. Thirdly, the potential impact of PVE on ductal tumor progression has not been defined. In addition, only a limited reduction in postoperative liver failure rate has been reported after PVE in patients with HCCA [18, 19], and excellent results have been obtained in a series of radical HCCA resections without the use of preoperative PVE [20]. In the present series, preoperative PVE was applied in 2 (5%) patients undergoing extended right hemihepatectomy. None of the 2 showed signs of liver failure in the postoperative period.

As an alternative to increasing liver parenchymal volume by PVE, the resection may be adapted to preserve as much liver parenchyma as possible. In selected cases, depending on the level where the bile ducts of segment 4 enter the area of the hepatic duct confluence, the cranial part of segment 4 (segment 4a) may be preserved when performing extended right hemihepatectomy. For left-sided tumors with central extension to the sectorial ducts of segments 5/8 and 6/7, a modified extended left hemihepatectomy may be performed limiting parenchymal resection on the right side to only segment 5 and the adjacent part of segment 8. This modification is feasible depending on proximal infiltration of tumor into the right segmental ducts and the anatomy of the right sectorial ducts (B5/8 and B6/7) in relation to the right hepatic duct on the one hand, and the main confluence of right and left hepatic ducts on the other. In patients in whom the bile ducts of segments 6 and 7 and the left lateral segments 2 and 3 are not infiltrated, a central liver resection (mesohepatectomy) can be considered, provided the afferent vasculature to these segments can be maintained.

Multiple jejunal anastomoses with intrahepatic segmental bile ducts are required in these cases. En bloc excision of segment 1 is recommended in most resections, irrespective of the extent of resection.

We recently reported hospital mortality of 10% in a previous series of patients (until 2003) after resection of HCCA, with an R0 resection rate of 59% and actuarial 5-year survival of 33% [21]. Refinements in preoperative preparation and reduction of the extent of parenchymal resection in selected cases of HCCA were accompanied by a decrease in overall mortality rate in our series to 7%. Since survival was not analyzed in the present series because of the short follow-up time, we do not know at this point, if the obtained reduction in mortality rate translates into improvement of overall survival. As the modified extended resections did not result in decreased R0 resection rate (92 vs. 59%), a decrease in survival time in the present series does not seem likely. This notion is furthermore supported by a recent report of Chen et al. [20], who found no difference in survival rates between major and reduced liver resections in patients who had undergone resection for HCCA.

In conclusion, strategies to optimize liver function and to reduce the extent of parenchymal resection while performing hilar resection in combination with extended hemihepatectomy were associated with a decrease in overall mortality. Showing an R0 resection rate of 92%, the use of modified extended resections did not result in less radical resections in this series.

Disclosure Statement

The authors have nothing to disclose.

References

- 1 Dinant S, Gerhards MF, Rauws EA, Busch OR, Gouma DJ, van Gulik TM: Improved outcome of resection of hilar cholangiocarcinoma (Klatskin tumor). *Ann Surg Oncol* 2006;13:872–880.
- 2 Ito F, Cho CS, Rikkers LF, Weber SM: Hilar cholangiocarcinoma: current management. *Ann Surg* 2009;250:210–218.
- 3 Jarnagin WR, Fong Y, DeMatteo RP, Gonen M, Burke EC, Bodniewicz BJ, Youssef BM, Klimstra D, Blumgart LH: Staging, resectability, and outcome in 225 patients with hilar cholangiocarcinoma. *Ann Surg* 2001;234:507–517.
- 4 Nimura Y, Kamiya J, Kondo S, Nagino M, Uesaka K, Oda K, Sano T, Yamamoto H, Hayakawa N: Aggressive preoperative management and extended surgery for hilar cholangiocarcinoma: Nagoya experience. *J Hepatobiliary Pancreat Surg* 2000;7:155–162.
- 5 Rocha FG, Matsuo K, Blumgart LH, Jarnagin WR: Hilar cholangiocarcinoma: the Memorial Sloan-Kettering Cancer Center experience. *J Hepatobiliary Pancreat Sci* 2010;17:490–496.
- 6 Bismuth H, Corlette MB: Intrahepatic cholangioenteric anastomosis in carcinoma of the hilus of the liver. *Surg Gynecol Obstet* 1975;140:170–178.
- 7 Dindo D, Demartines N, Clavien PA: Classification of surgical complications: a new proposal with evaluation in a cohort of 6336 patients and results of a survey. *Ann Surg* 2004;240:205–213.
- 8 van Gulik TM, Dinant S, Busch OR, Rauws EA, Obertop H, Gouma DJ: Original article: new surgical approaches to the Klatskin tumour. *Aliment Pharmacol Ther* 2007;26 (suppl 2):127–132.

- 9 Castaing D: Surgical anatomy of the biliary tract. *HPB (Oxford)* 2008;10:72–76.
- 10 Dinant S, de GW, Verwer BJ, Bennink RJ, van Lienden KP, Gouma DJ, van Vliet AK, van Gulik TM: Risk assessment of posthepatectomy liver failure using hepatobiliary scintigraphy and CT volumetry. *J Nucl Med* 2007;48:685–692.
- 11 van der Gaag NA, Kloek JJ, de Castro SM, Busch OR, van Gulik TM, Gouma DJ: Preoperative biliary drainage in patients with obstructive jaundice: history and current status. *J Gastrointest Surg* 2009;13:814–820.
- 12 Kloek JJ, van der Gaag NA, Aziz Y, Rauws EA, van Delden OM, Lameris JS, Busch OR, Gouma DJ, van Gulik TM: Endoscopic and percutaneous preoperative biliary drainage in patients with suspected hilar cholangiocarcinoma. *J Gastrointest Surg* 2010;14:119–125.
- 13 Dinant S, Gerhards MF, Busch OR, Obertop H, Gouma DJ, van Gulik TM: The importance of complete excision of the caudate lobe in resection of hilar cholangiocarcinoma. *HPB (Oxford)* 2005;7:263–267.
- 14 Nimura Y: Preoperative biliary drainage before resection for cholangiocarcinoma (Pro). *HPB (Oxford)* 2008;10:130–133.
- 15 van der Gaag NA, Rauws EA, van Eijck CH, Bruno MJ, van der Harst E, Kubben FJ, Geritsen JJ, Greve JW, Gerhards MF, de Hingh IH, Klinkenbijnl JH, Nio CY, de Castro SM, Busch OR, van Gulik TM, Bossuyt PM, Gouma DJ: Preoperative biliary drainage for cancer of the head of the pancreas. *N Engl J Med* 2010;362:129–137.
- 16 Nagino M, Kamiya J, Nishio H, Ebata T, Arai T, Nimura Y: Two hundred forty consecutive portal vein embolizations before extended hepatectomy for biliary cancer: surgical outcome and long-term follow-up. *Ann Surg* 2006;243:364–372.
- 17 van Gulik TM, van den Esschert JW, de Graaf W, van Lienden KP, Busch OR, Heger M, van Delden OM, Lameris JS, Gouma DJ: Controversies in the use of portal vein embolization. *Dig Surg* 2008;25:436–444.
- 18 Rea DJ, Munoz-Juarez M, Farnell MB, Donohue JH, Que FG, Crownhart B, Larson D, Nagorney DM: Major hepatic resection for hilar cholangiocarcinoma: analysis of 46 patients. *Arch Surg* 2004;139:514–523.
- 19 Kawasaki S, Imamura H, Kobayashi A, Noike T, Miwa S, Miyagawa S: Results of surgical resection for patients with hilar bile duct cancer: application of extended hepatectomy after biliary drainage and hemihepatic portal vein embolization. *Ann Surg* 2003;238:84–92.
- 20 Chen XP, Lau WY, Huang ZY, Zhang ZW, Chen YF, Zhang WG, Qiu FZ: Extent of liver resection for hilar cholangiocarcinoma. *Br J Surg* 2009;96:1167–1175.
- 21 van Gulik TM, Kloek JJ, Ruys AT, Busch OR, van Tienhoven GJ, Lameris JS, Rauws EA, Gouma DJ: Multidisciplinary management of hilar cholangiocarcinoma (Klatskin tumor): extended resection is associated with improved survival. *Eur J Surg Oncol* 2011; 37:65–71.